

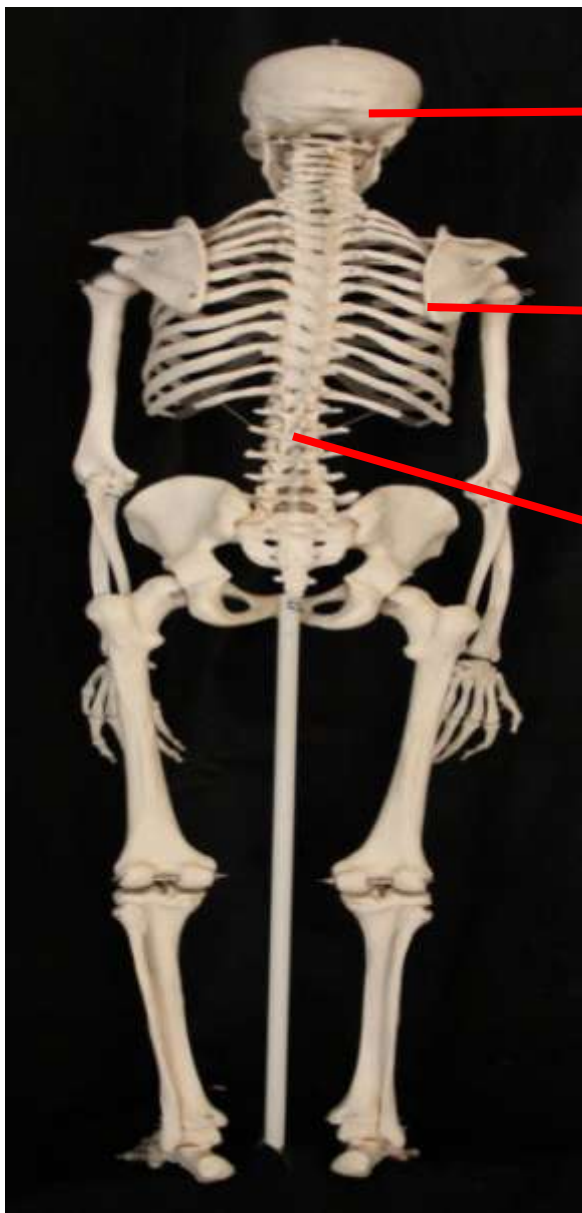

SISTEMA ESQUELÉTICO

Funções: suporte, movimento, proteção, estoque de minerais e hematopoiese.

O esqueleto humano consiste em 206 ossos agrupados em **esqueleto axial** e **apendicular**.

*Esqueleto
Axial*

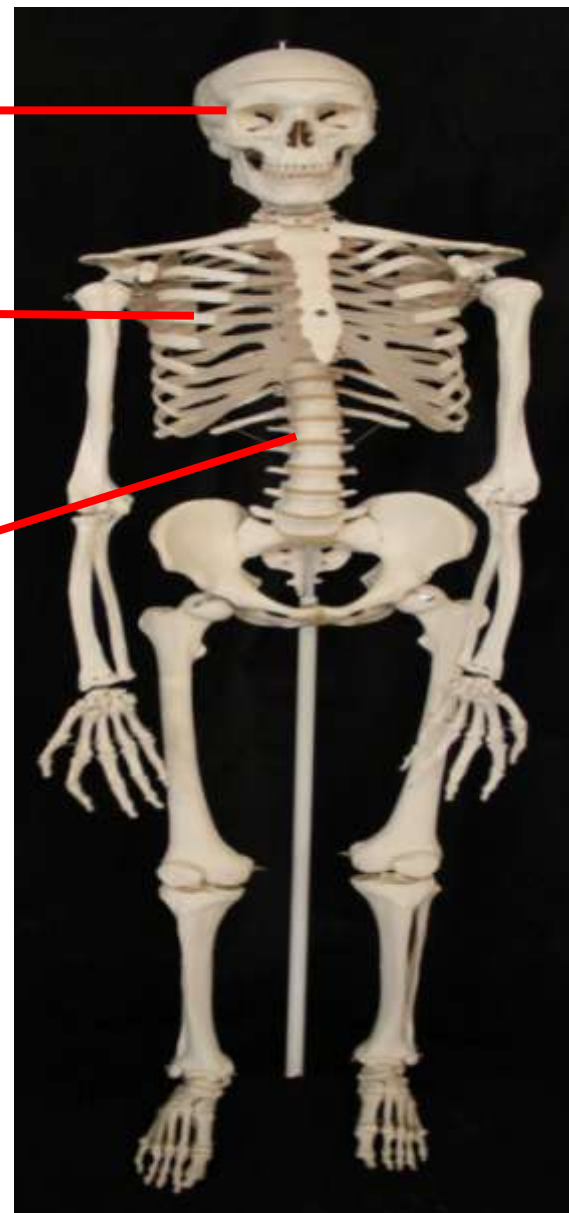

Vista posterior

Ossos do
Crânio

Ossos
Caixa
torácica

Ossos da
Coluna
vertebral



Vista anterior

Ossos do Crânio

Frontal

Parietal

Nasal

**Canal
óptico**

Temporal

Zigomático

**Conchas
Nasais**

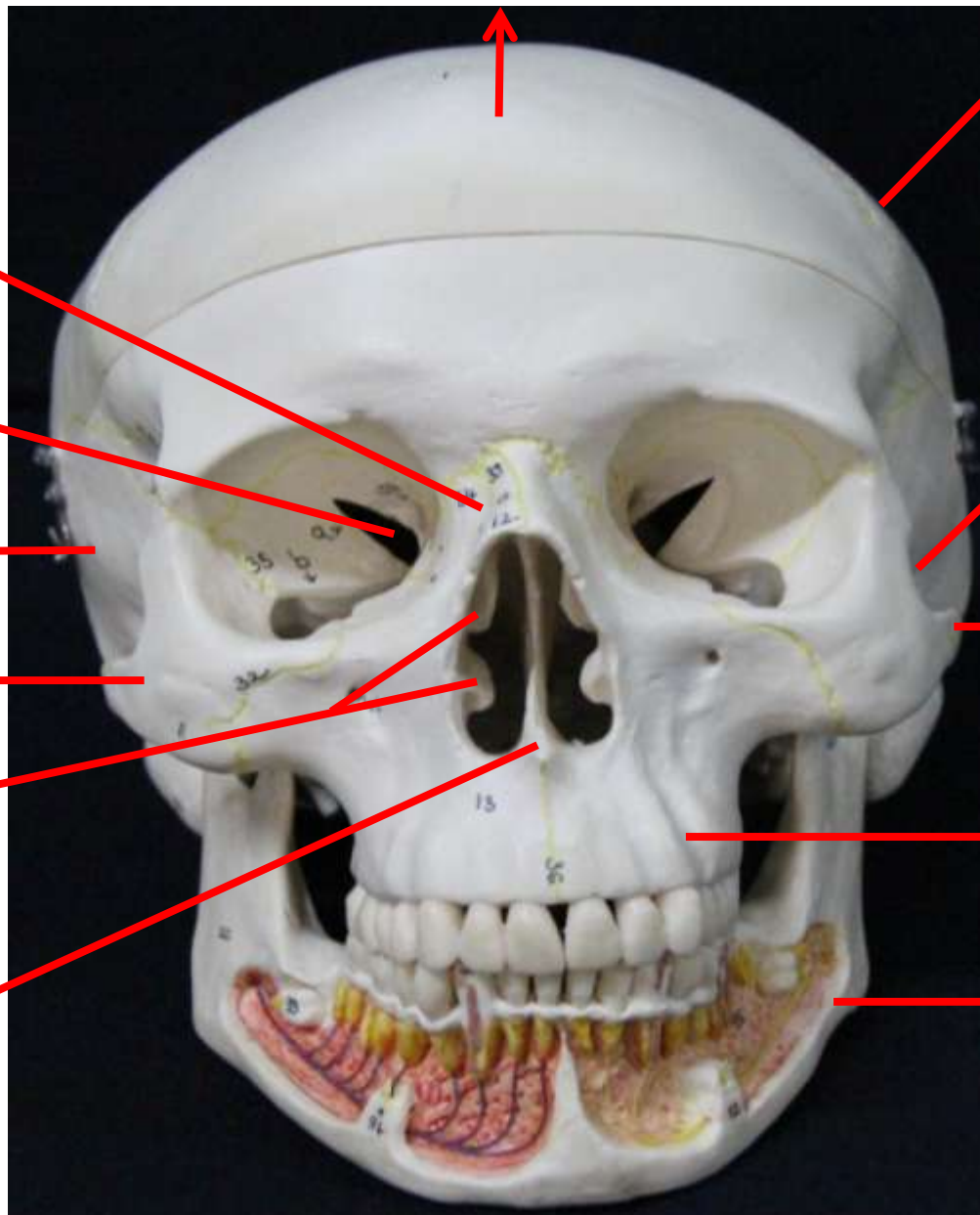
Vômer

Esfenoide

**Processo
zigomático
do osso
temporal**

Maxila

Mandíbula



Crânio vista anterior

Esfenoide

Frontal

Parietal

Fossa lacrimal

Nasal

Vômer

Maxilar

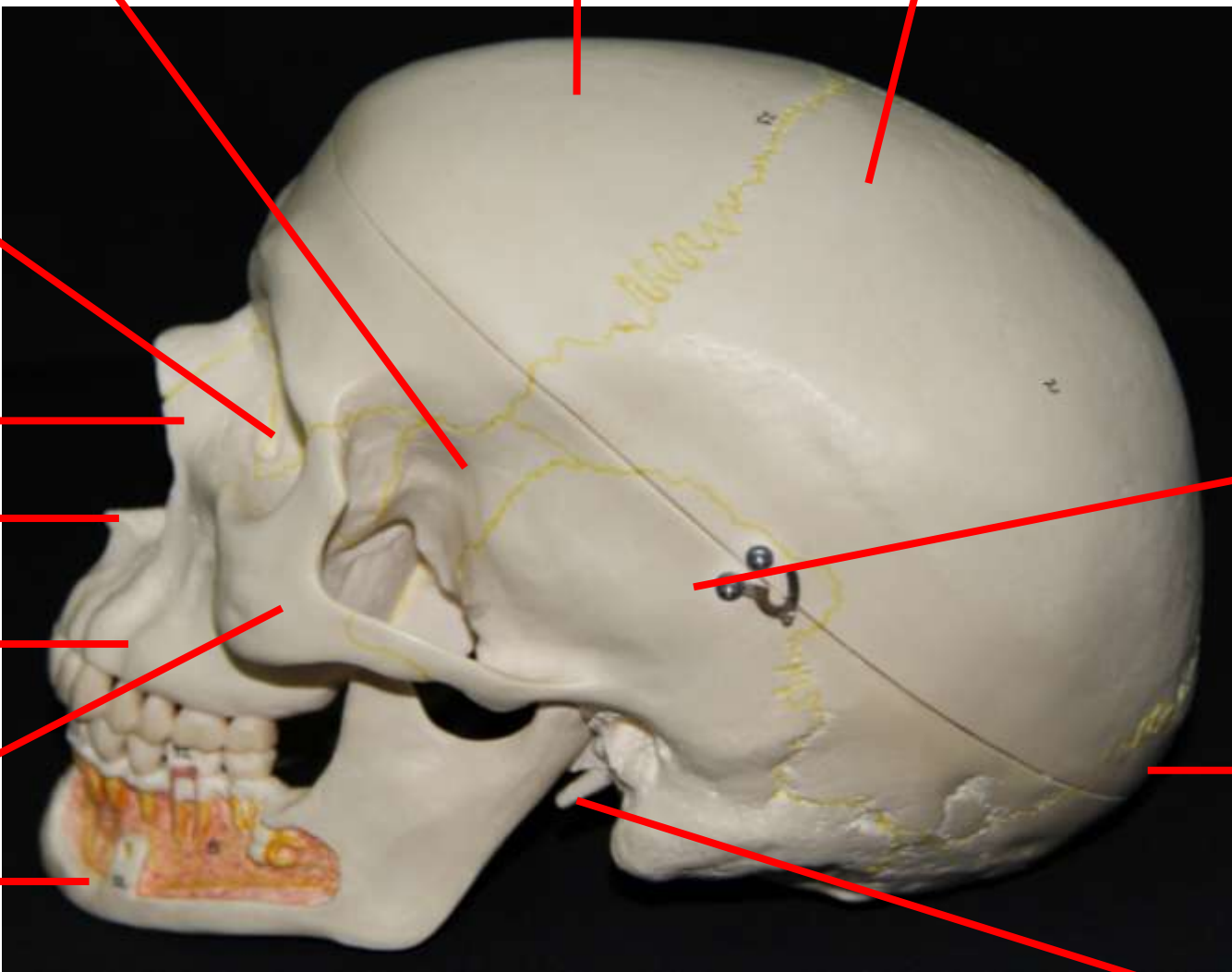
Zigomático

Mandíbula

Temporal

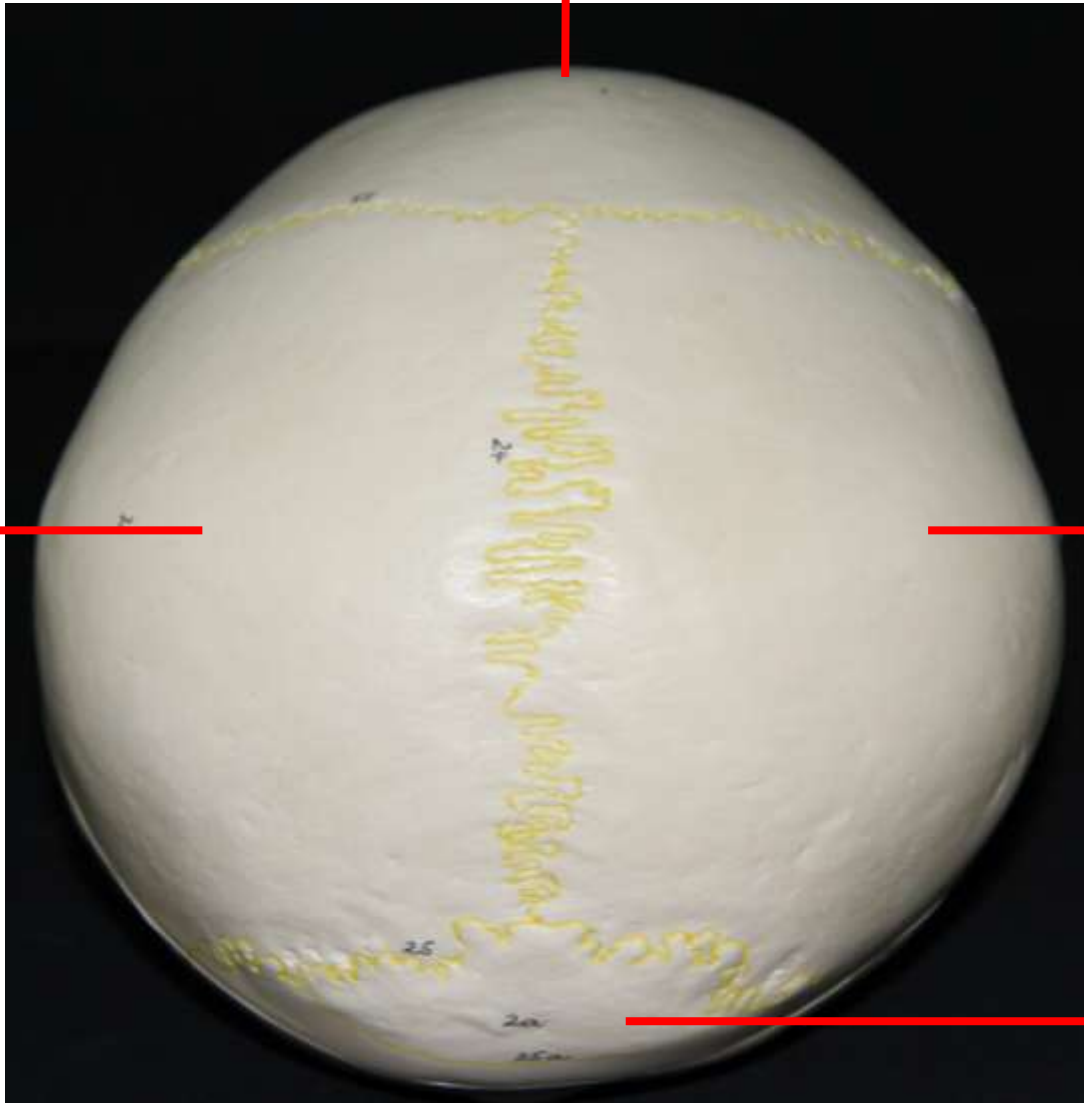
Occipital

Processo estilóide



Crânio vista lateral esquerda

Frontal



Parietal

Parietal

Occipital

Crânio
Vista Superior

Occipital

Parietal

Temporal

Temporal

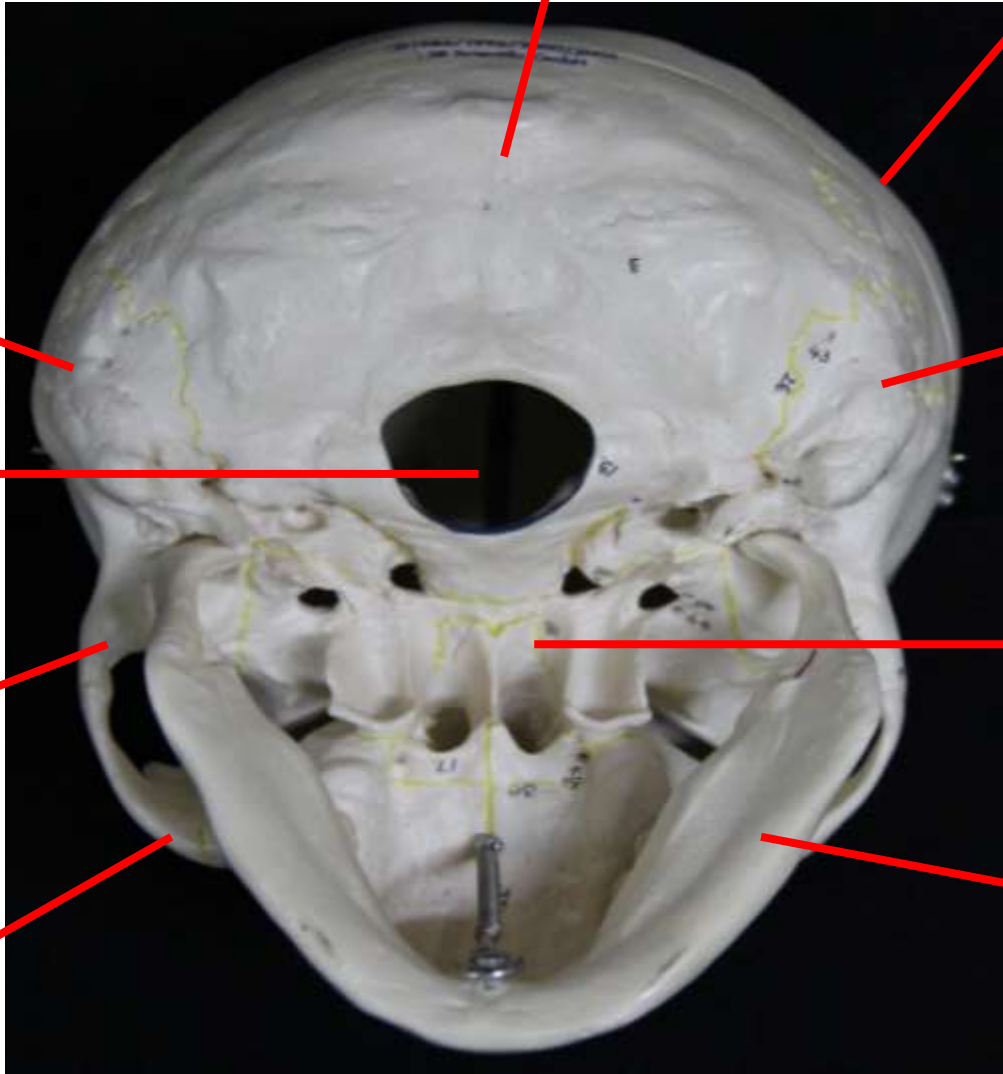
Forame magno

Processo zigomático do osso temporal

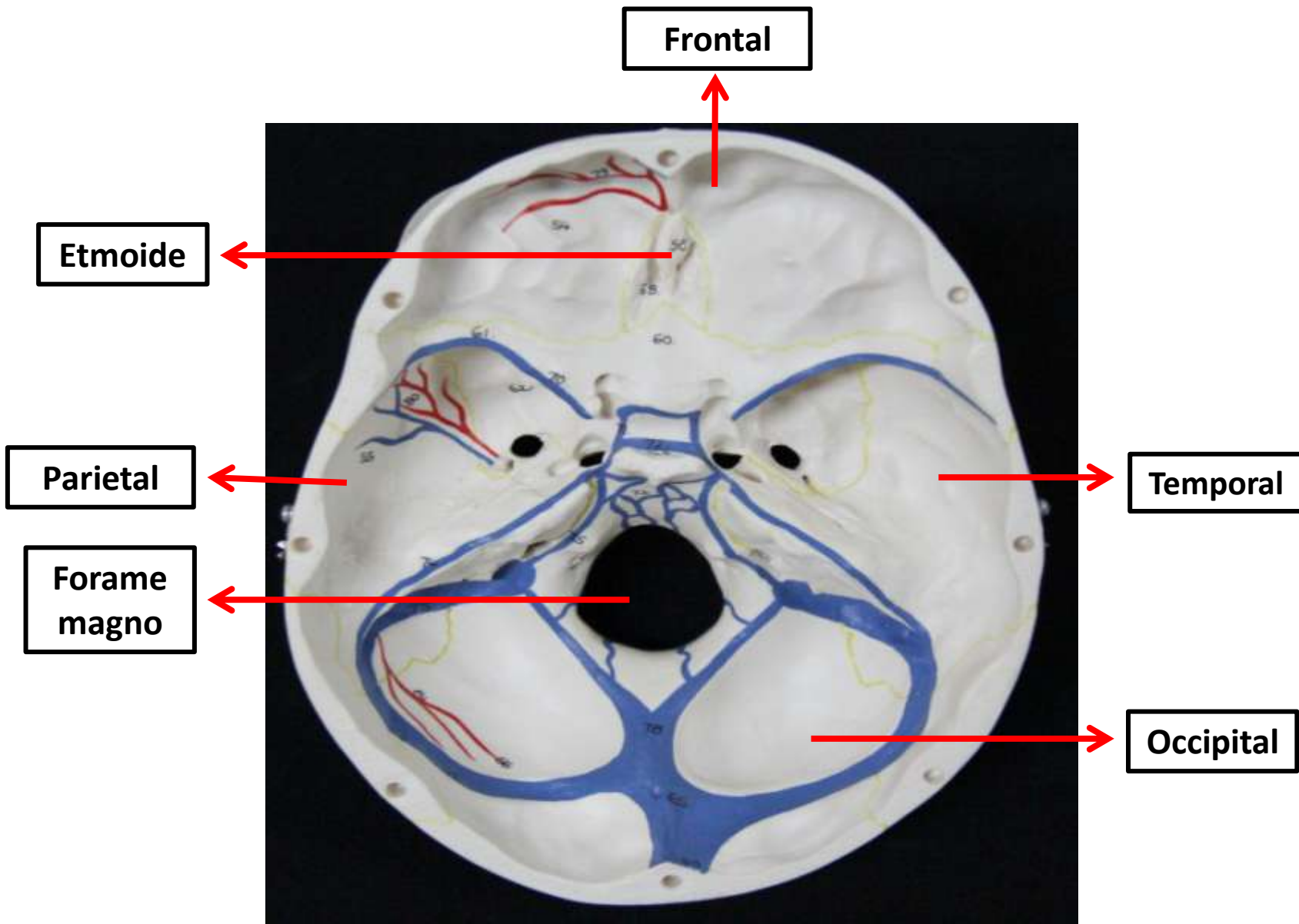
Zigomático

Esfenoide

Mandíbula



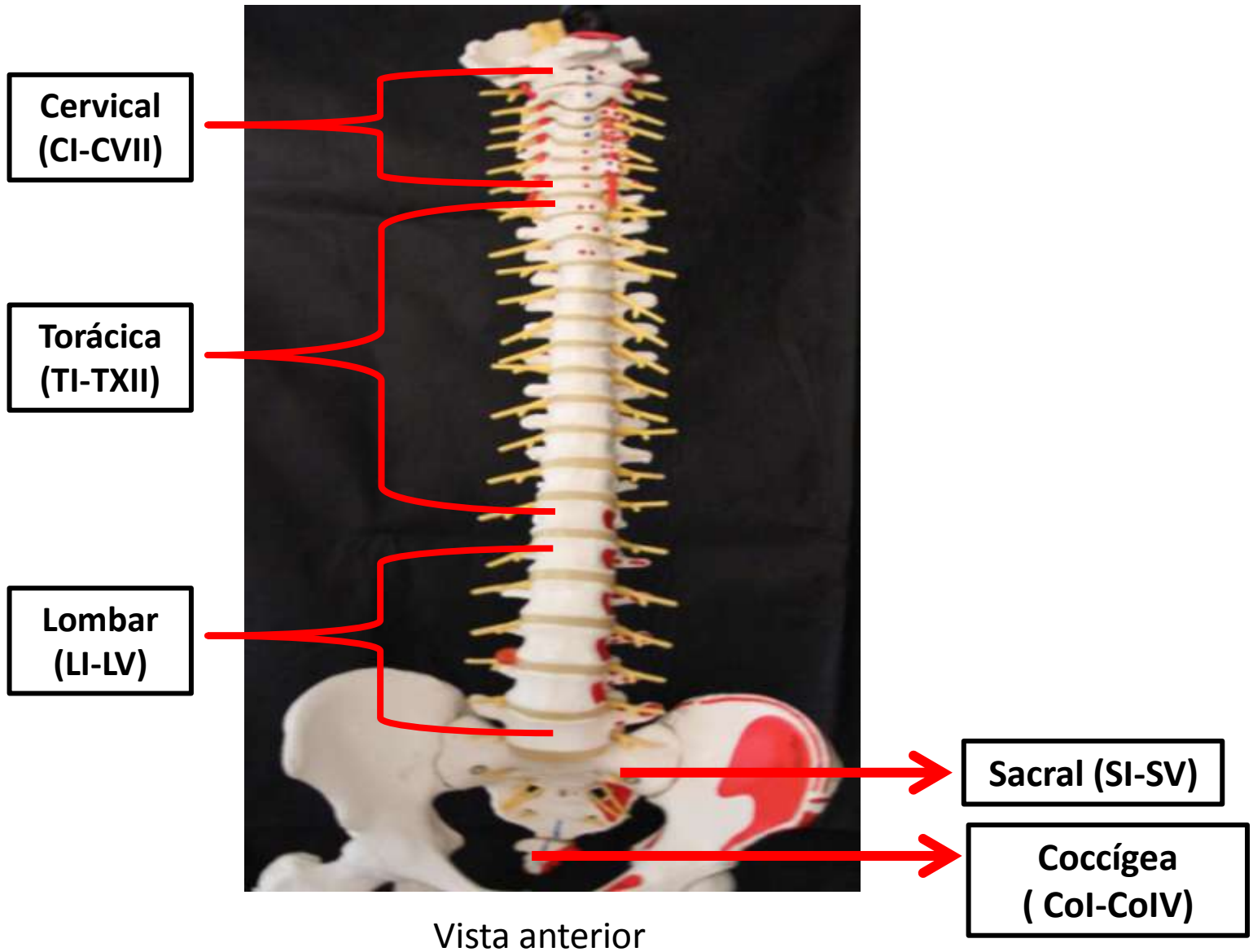
Crânio vista inferior
(base do crânio -vista externa)



Crânio corte frontal
(base do crânio – vista inferior)

Ossos da coluna vertebral

Regiões da Coluna Vertebral



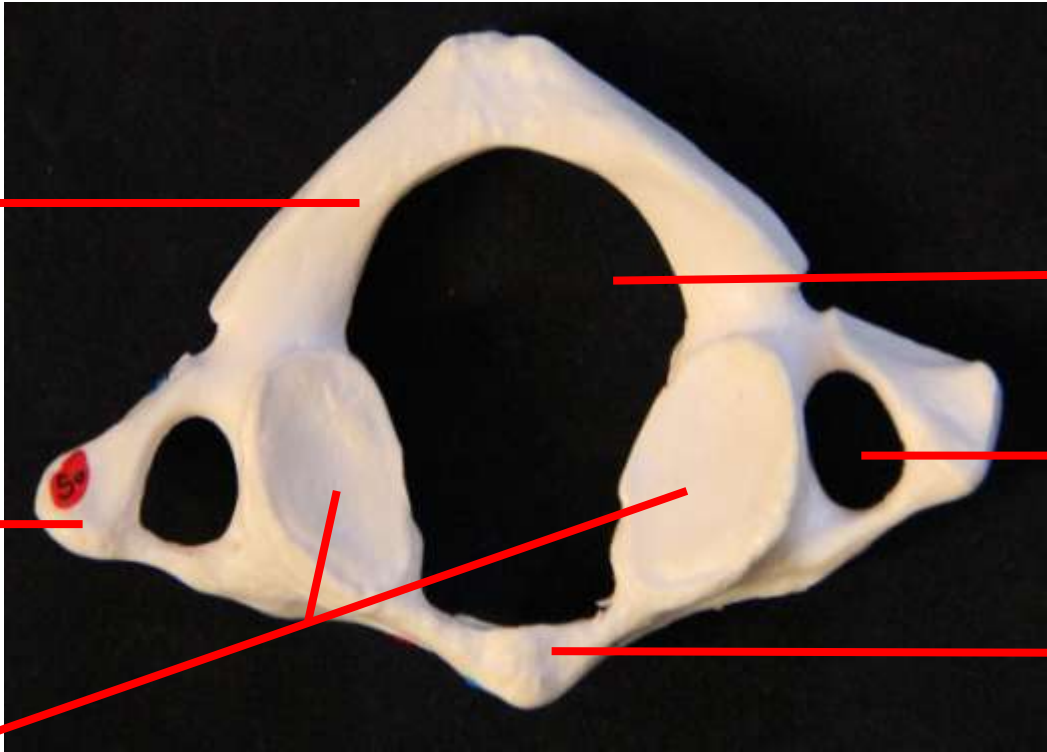
Vértebras Cervicais *(C1 e C2)*

Atlas (C1)

Arco posterior

Processo transverso

Facetas articulares



Forame vertebral

Forame transverso

Arco anterior

Vista Superior

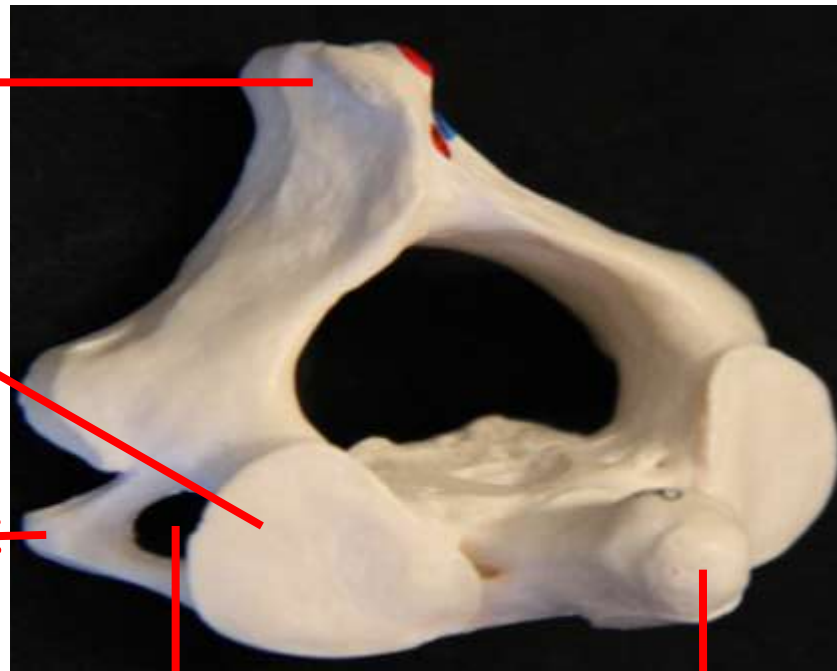Áxis
(C2)

Processo espinhoso

Faceta articular superior

Processo transverso

Processo espinhoso



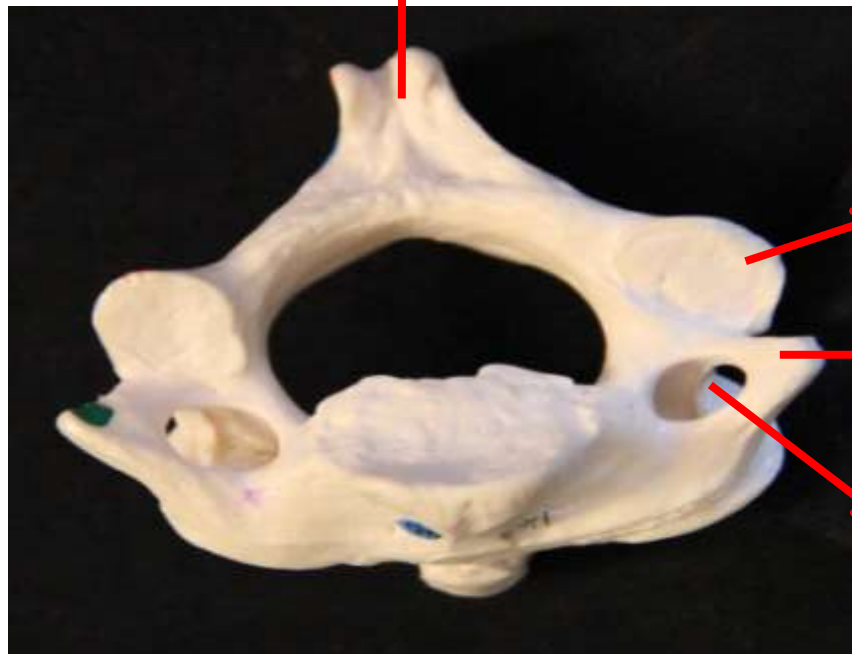Vista Superior

Dente

Faceta articular inferior

Processo transverso

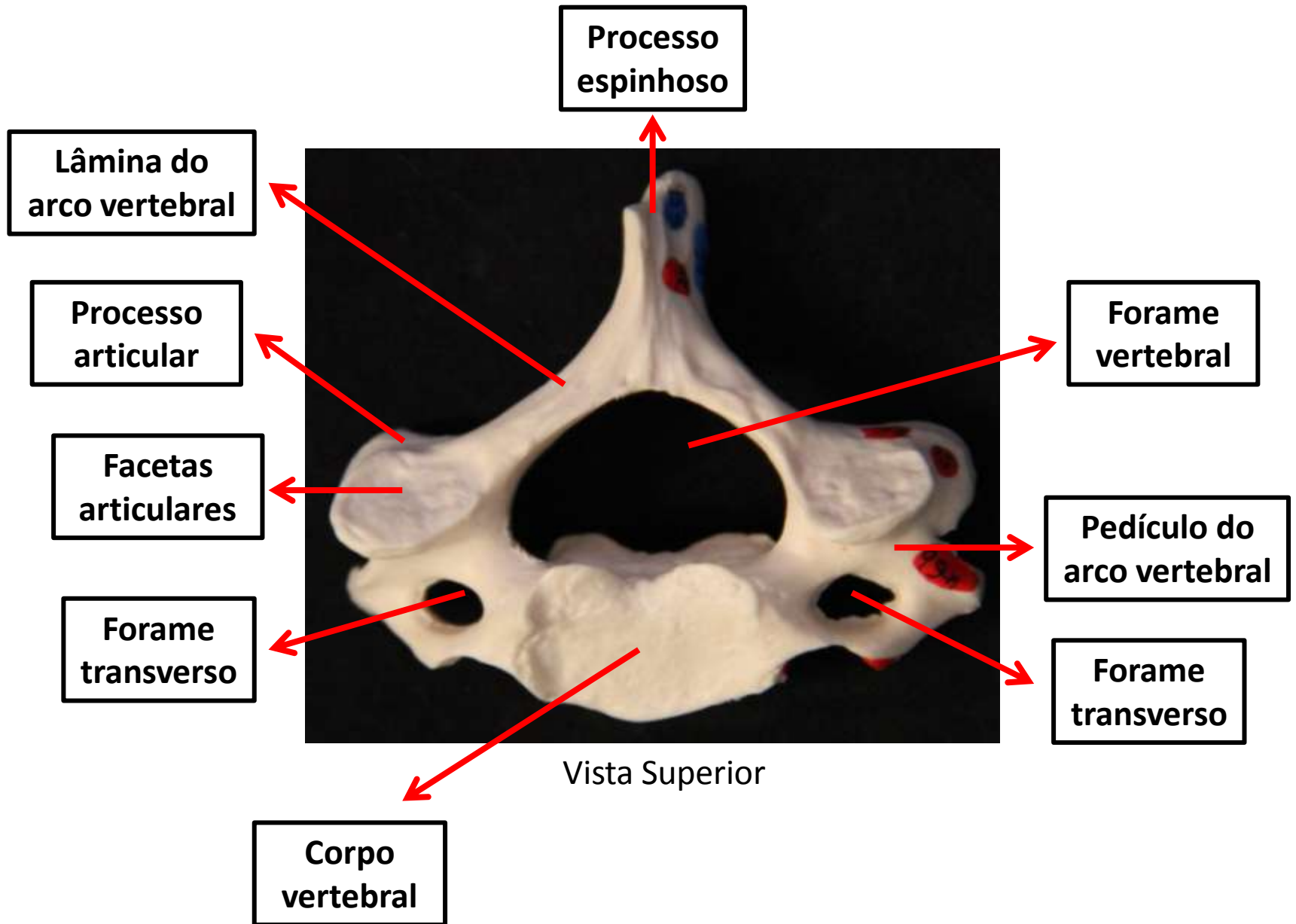
Forame transverso



Vista Inferior

Regiões e processos nas vértebras

Vértebra Cervical



Vértebra torácica

Processo
espinhoso

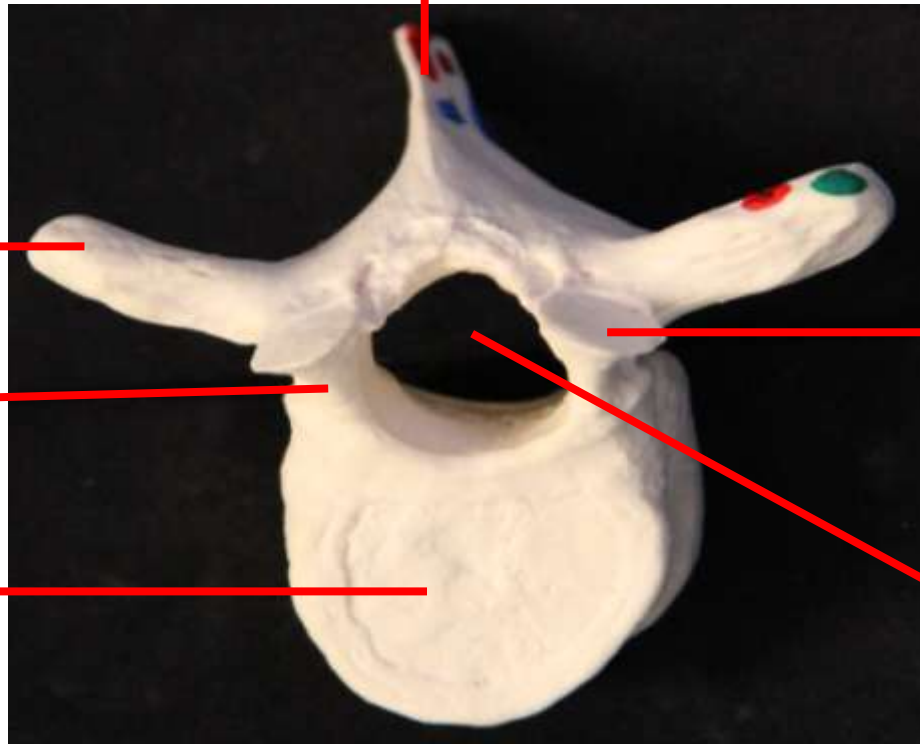
Processo
transverso

Pedículo do
arco vertebral

Corpo
vertebral

Faceta
articular

Forame
vertebral



Vista Superior

Vértebra Lombar

Processo
espinhoso

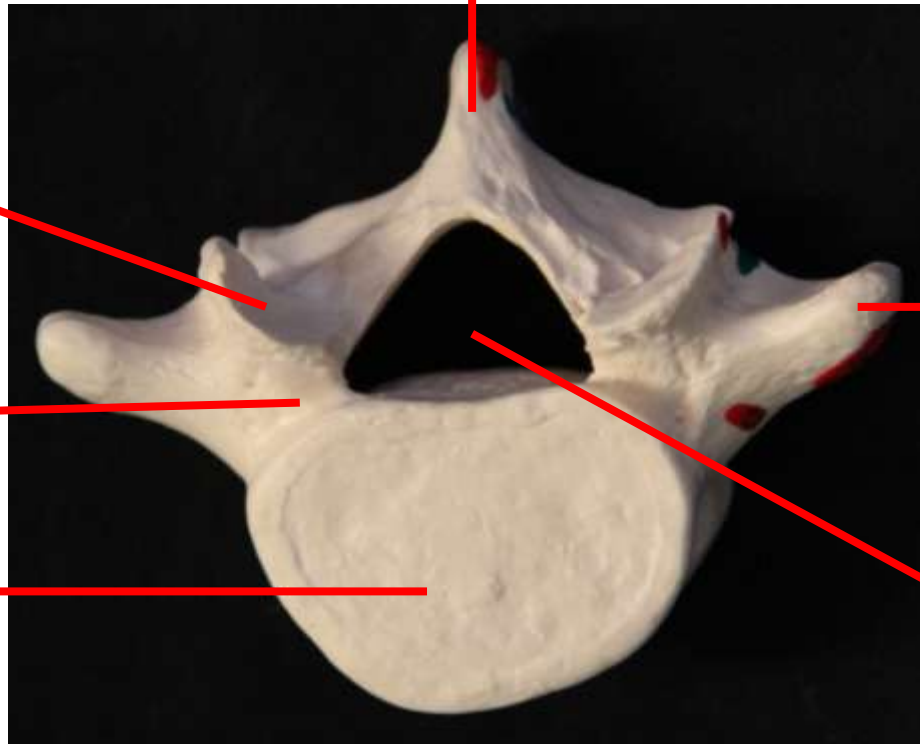
Faceta
articular

Pedículo do
arco vertebral

Corpo
vertebral

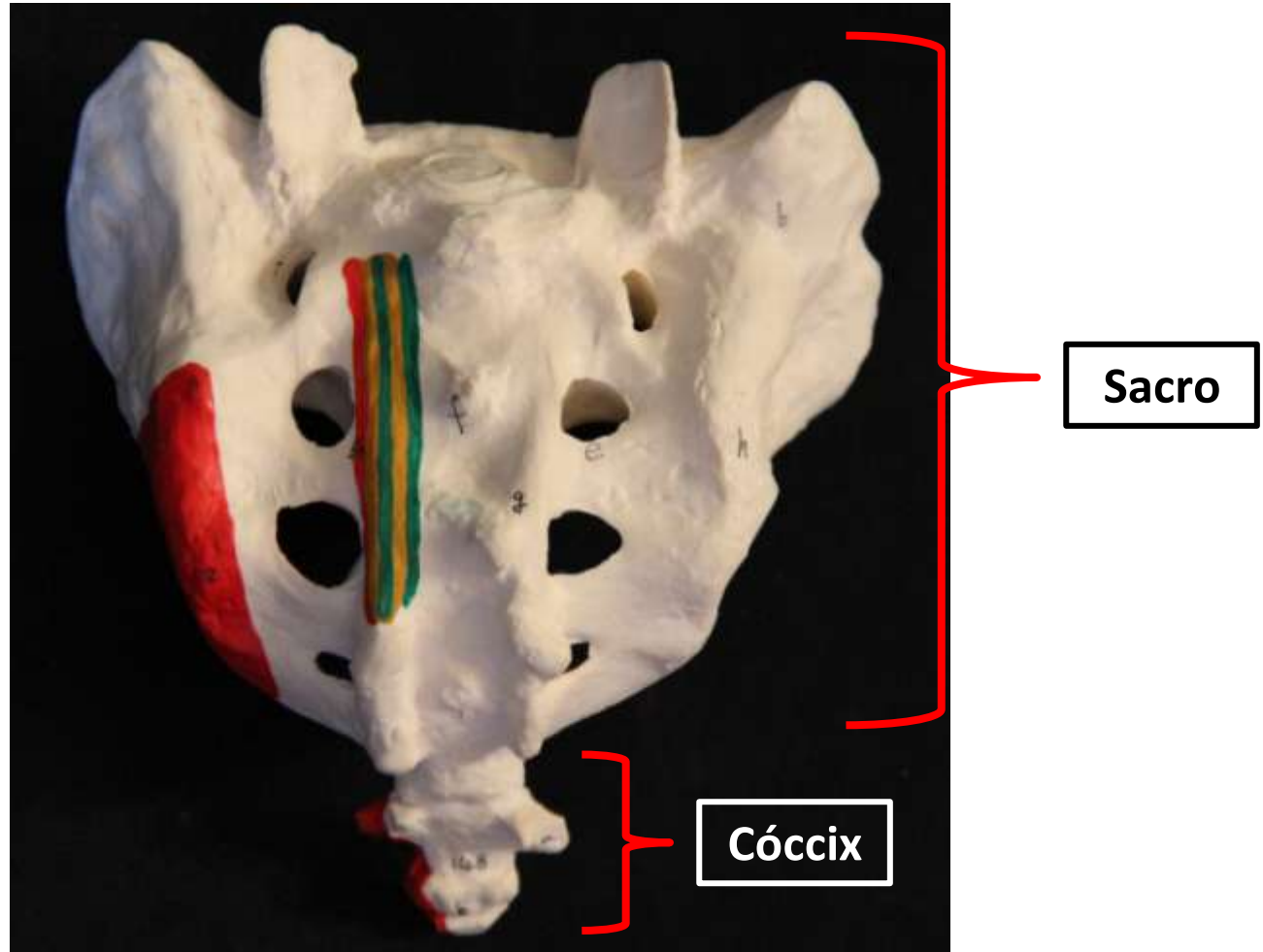
Processo
transverso

Forame
vertebral



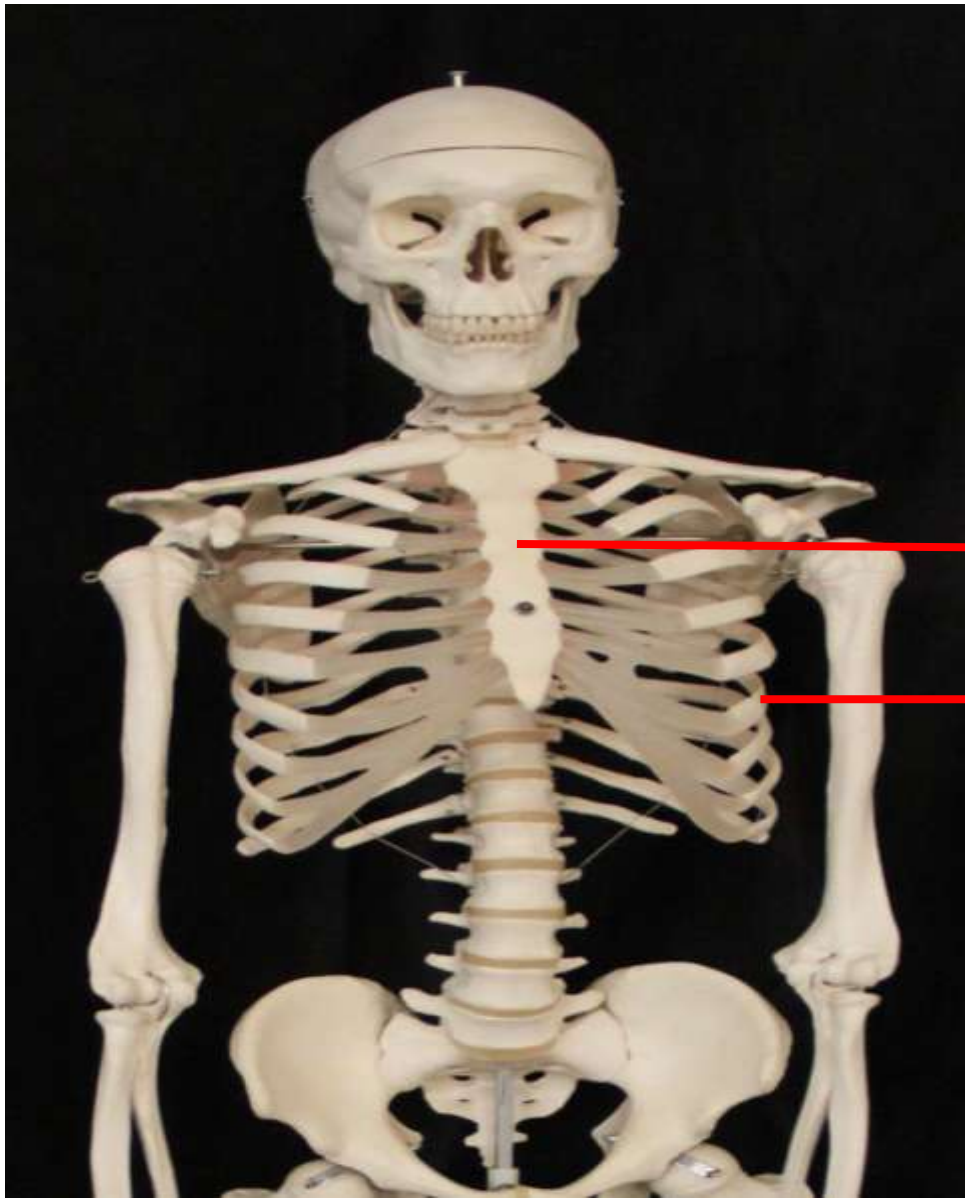
Vista Superior

Vértebras Sacrais e Coccígeas



Vista Posterior

Ossos do tórax

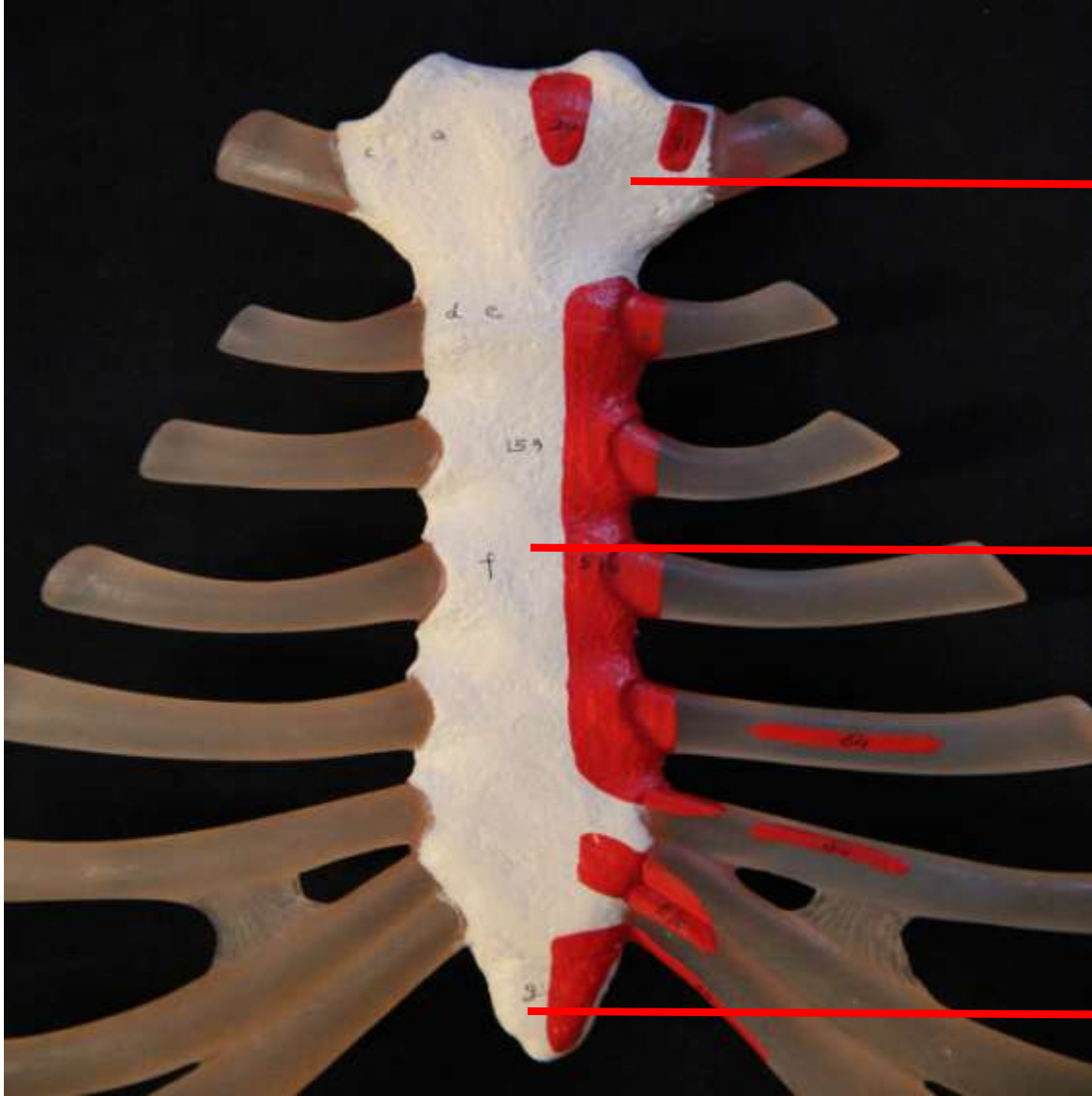


Esterno

Costelas

Caixa
Torácica

Vista anterior



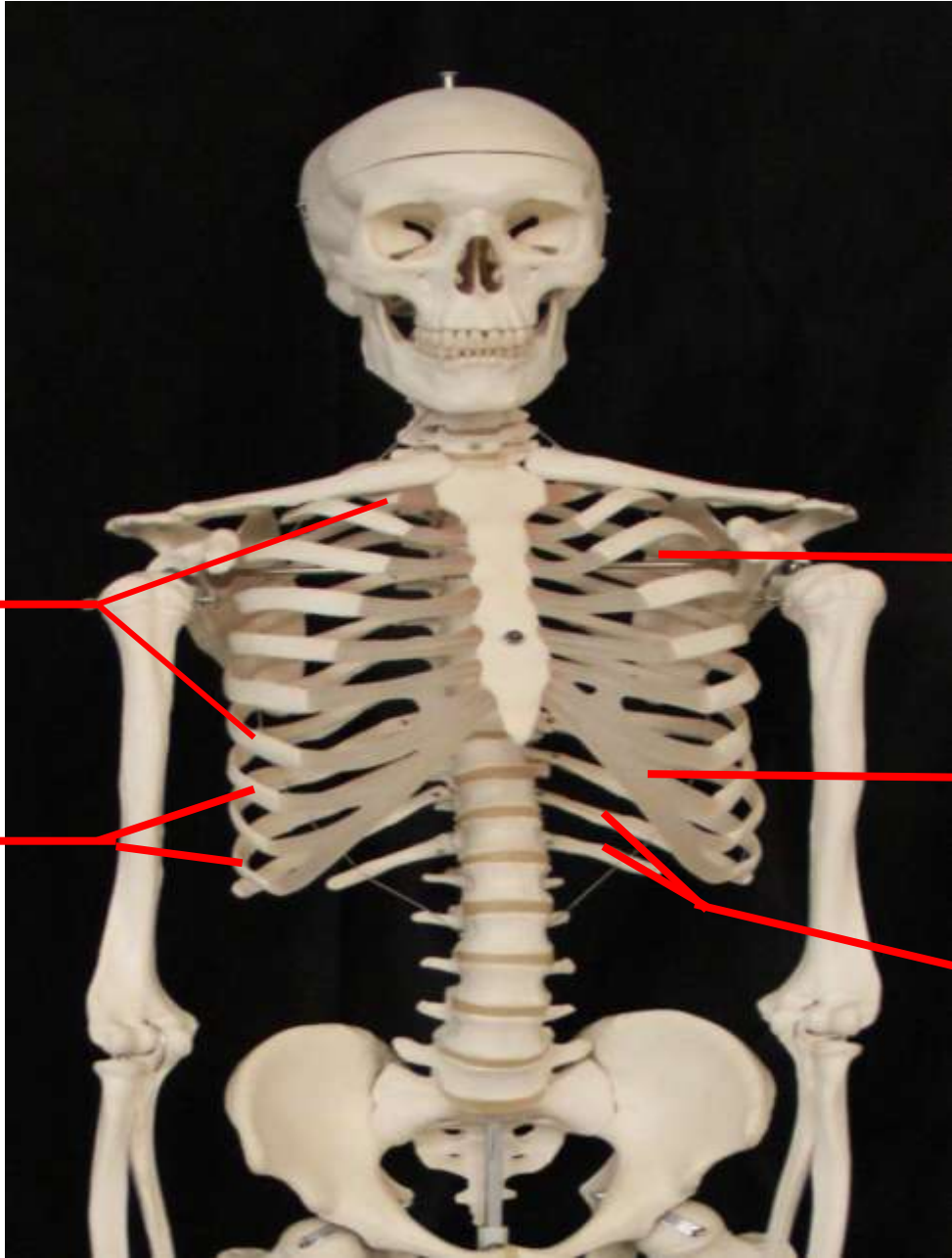Manúbrio
do
externo

Corpo do
externo

Processo
xifóide

Esterno

Vista anterior



Costelas verdadeiras (I-VII)

Costelas falsas (VIII-X)

Espaço intercostal

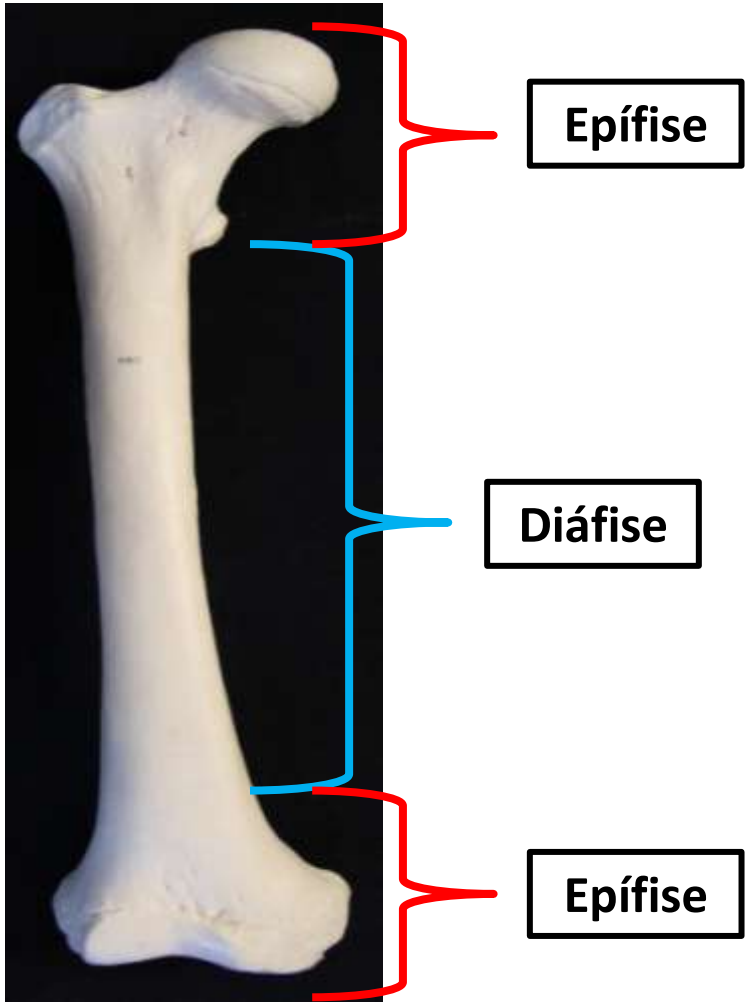
Cartilagens costais

Costelas Flutuantes (XI-XII)

Vista anterior

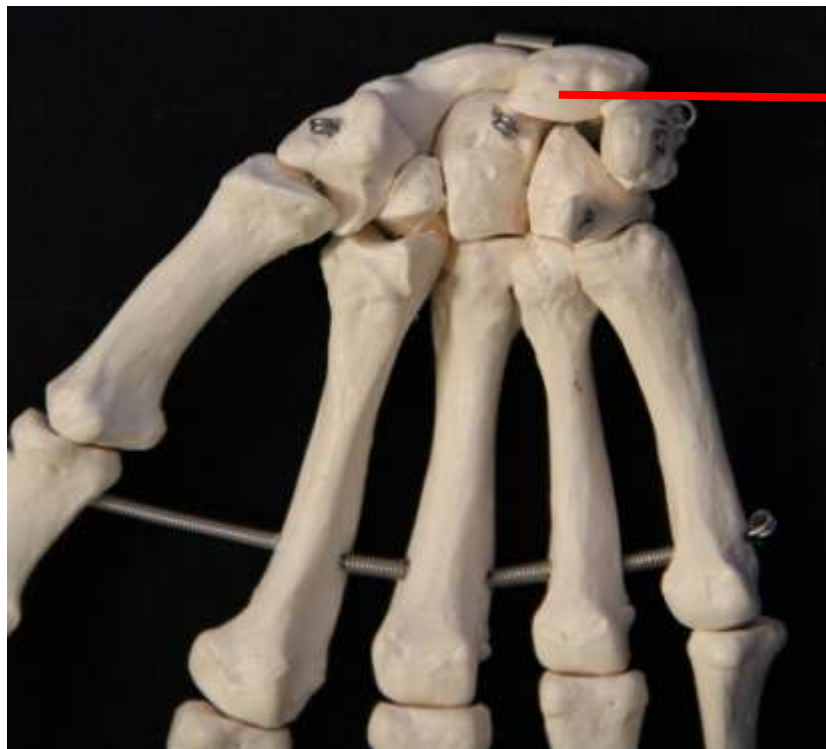
Tipos de Ossos

Longo



Fêmur - Vista anterior

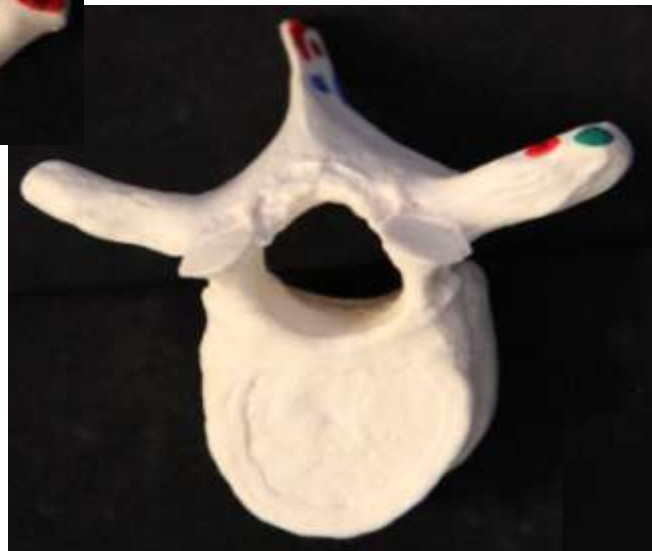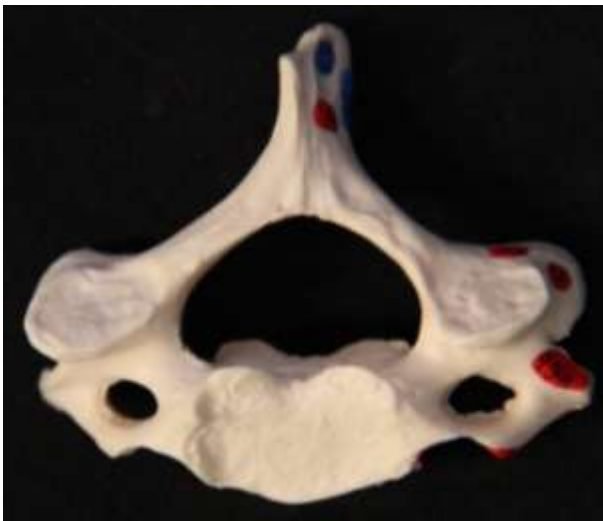
Curto



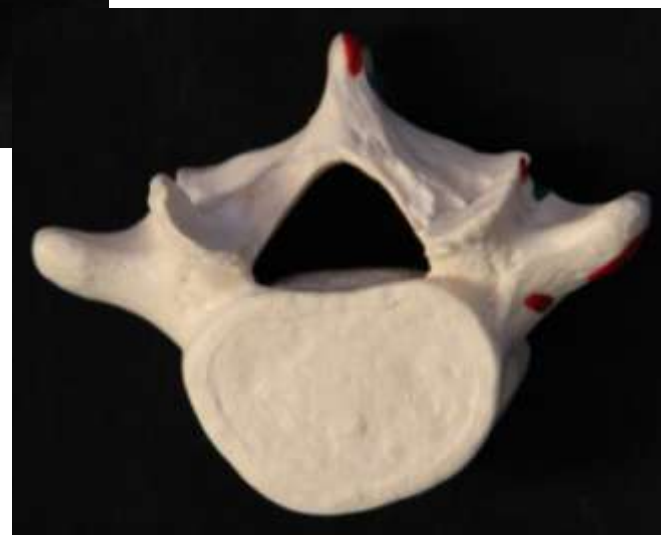**Ossos do
carpo**

Mão - Vista anterior

Irregular

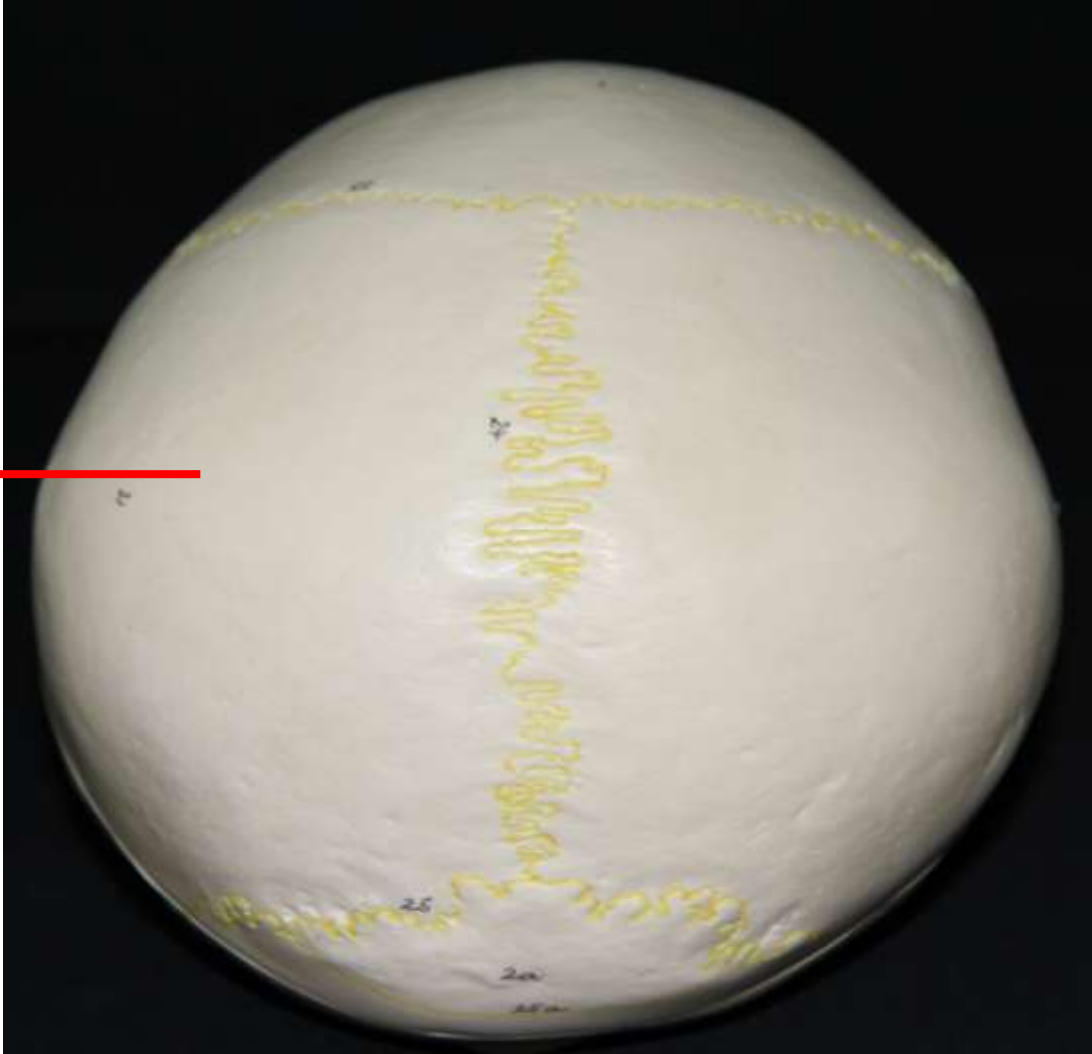



Vértebras - Vista Superior




Plano

Parietal



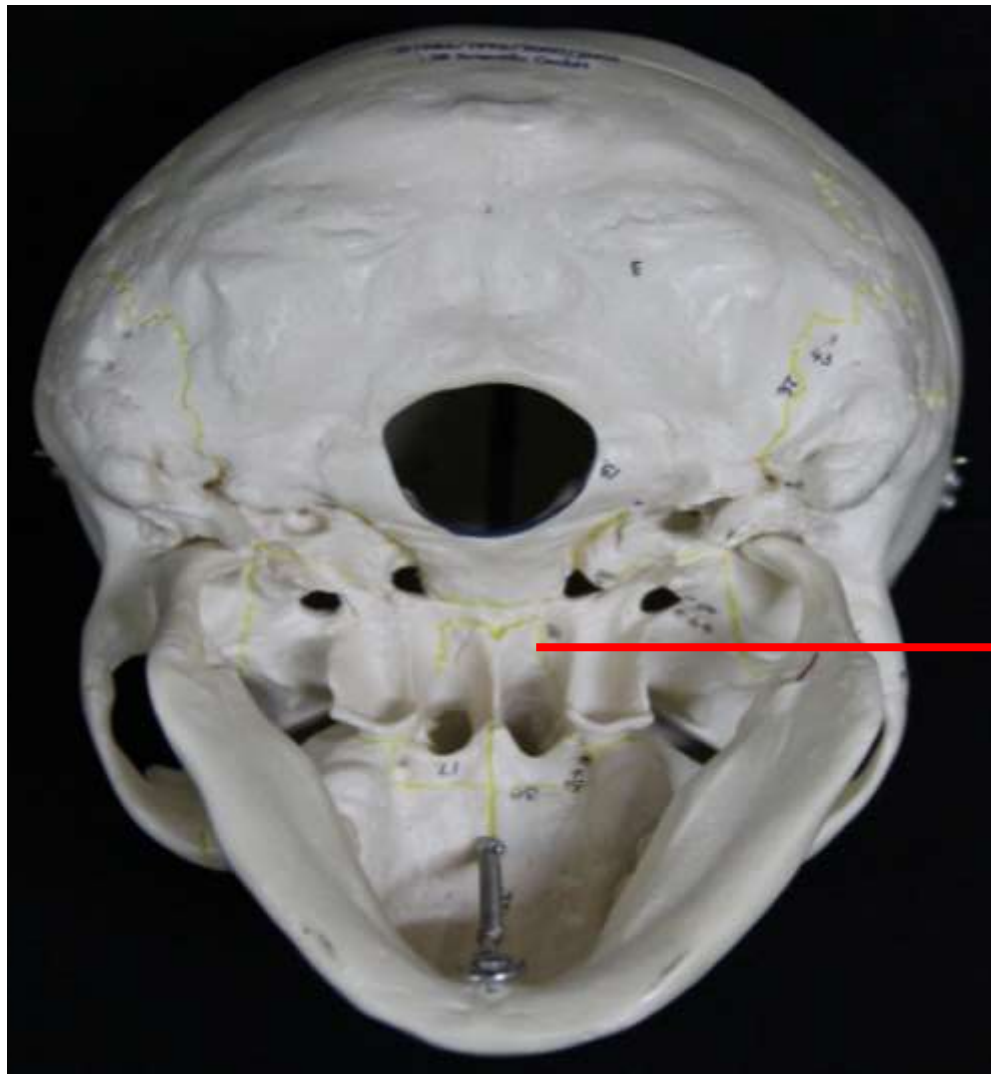
Crânio - Vista Superior

Sesamóide



Patela - Vista Superior

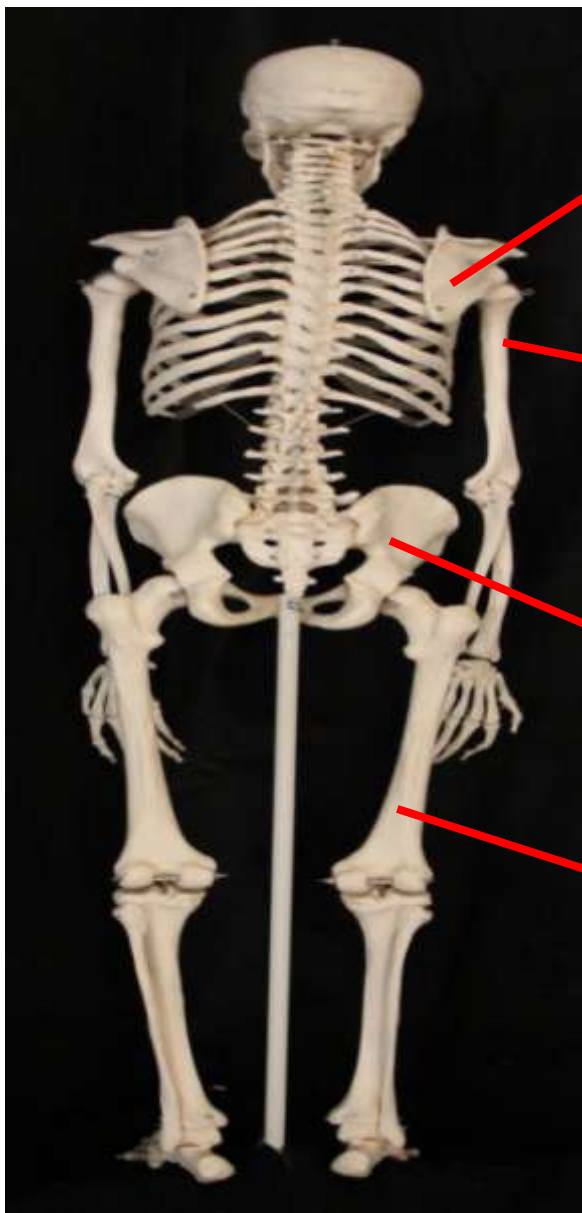
Pneumático



Esfenoide

Crânio vista inferior
(base do crânio - vista externa)

*Esqueleto
Apendicular*



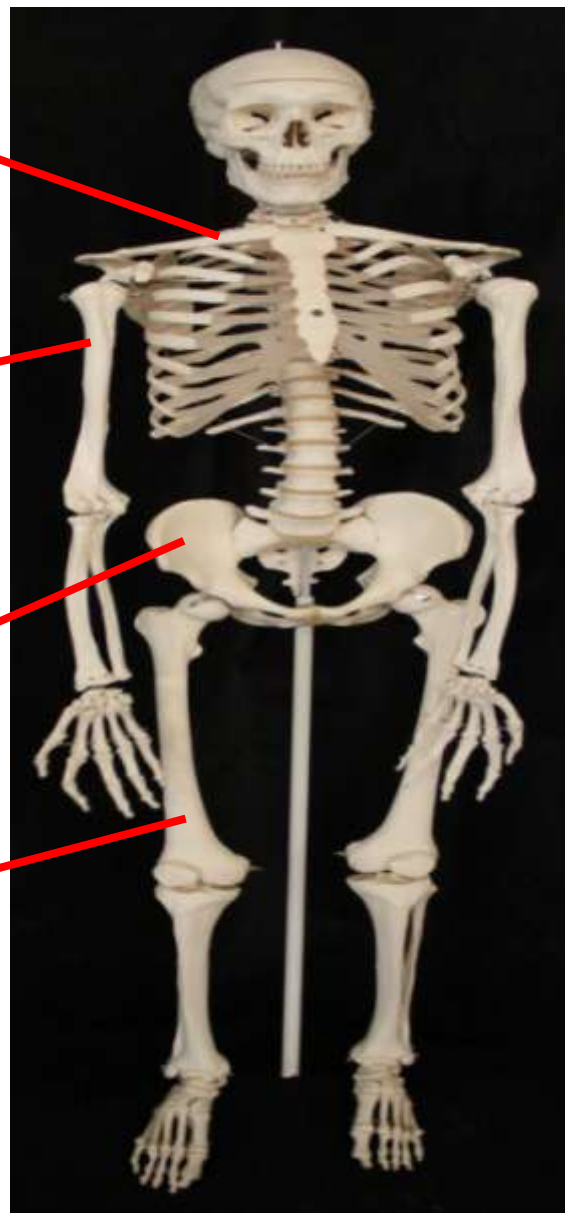
Vista anterior

Ossos do cingulo
do Membro
superior

Ossos do
Membro
Superior

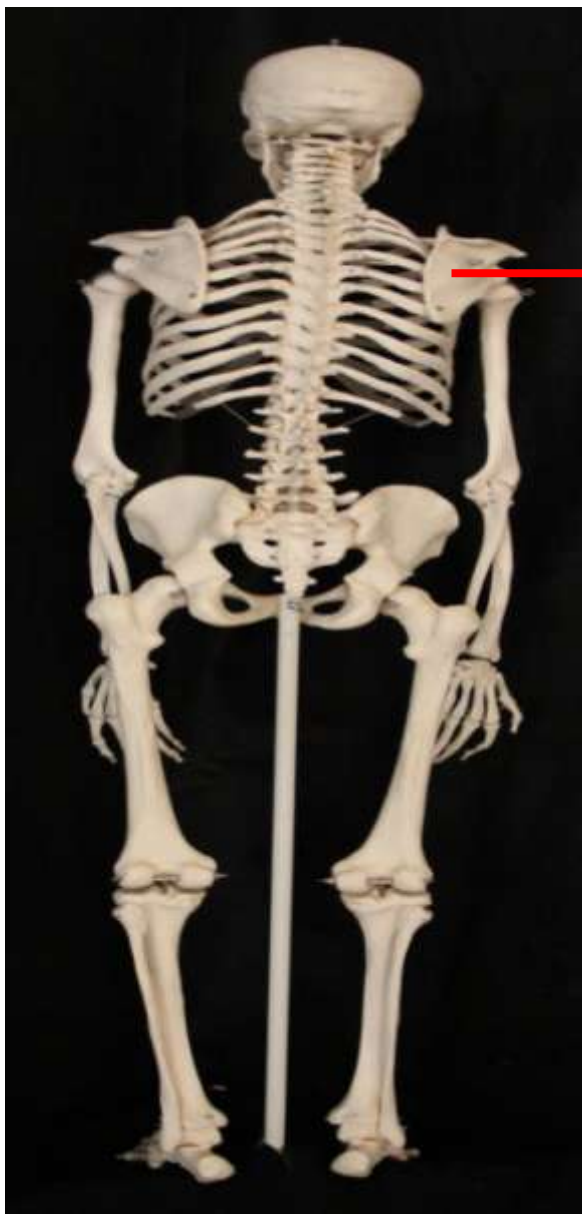Ossos do cingulo
do Membro
Inferior

Ossos do
Membro
Inferior



Vista posterior

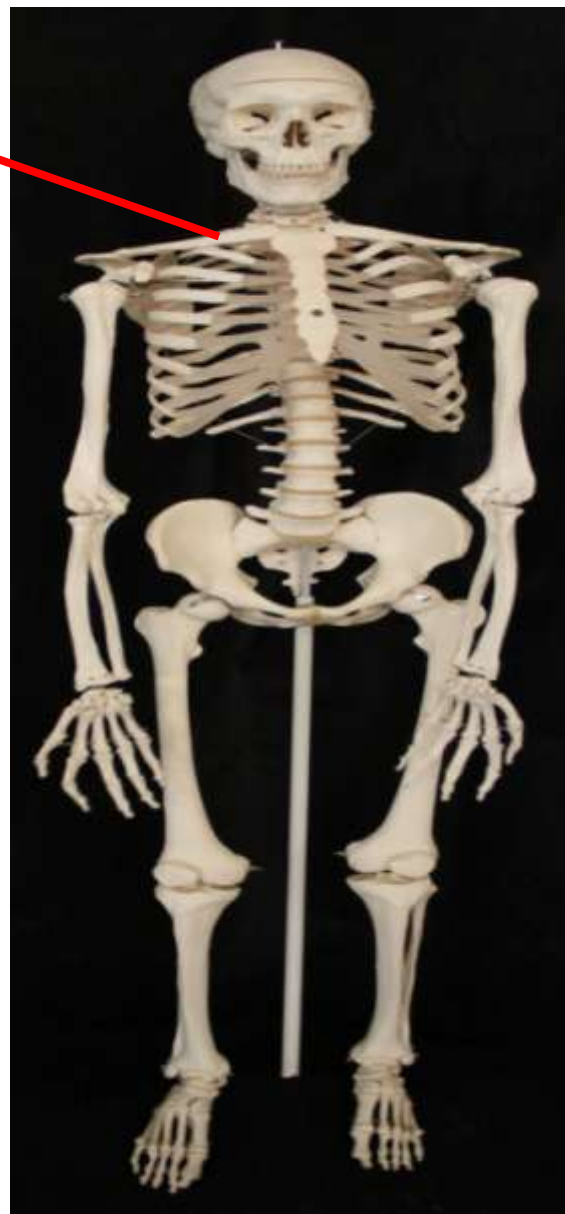*Ossos do Cíngulo
do Membro
Superior*



Vista anterior

Escápula

Clavícula

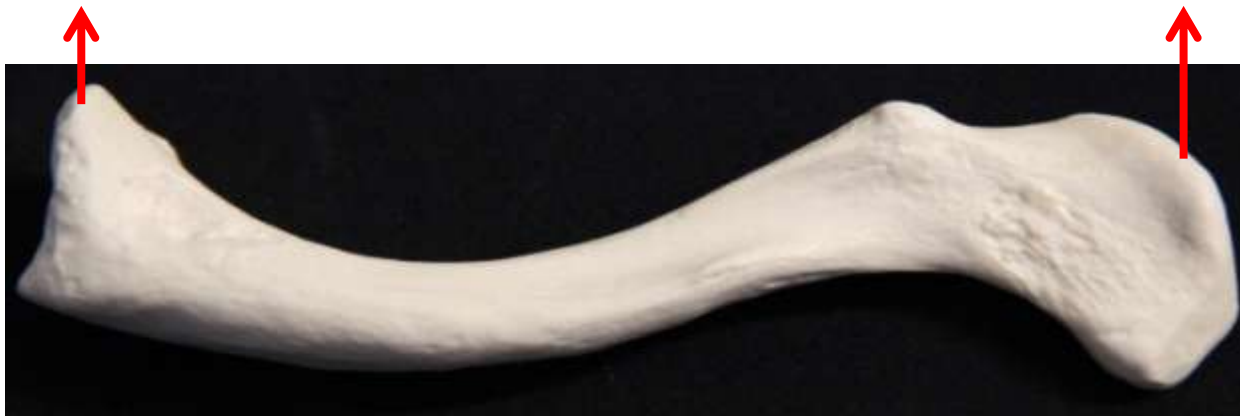

Vista posterior

Clavícula

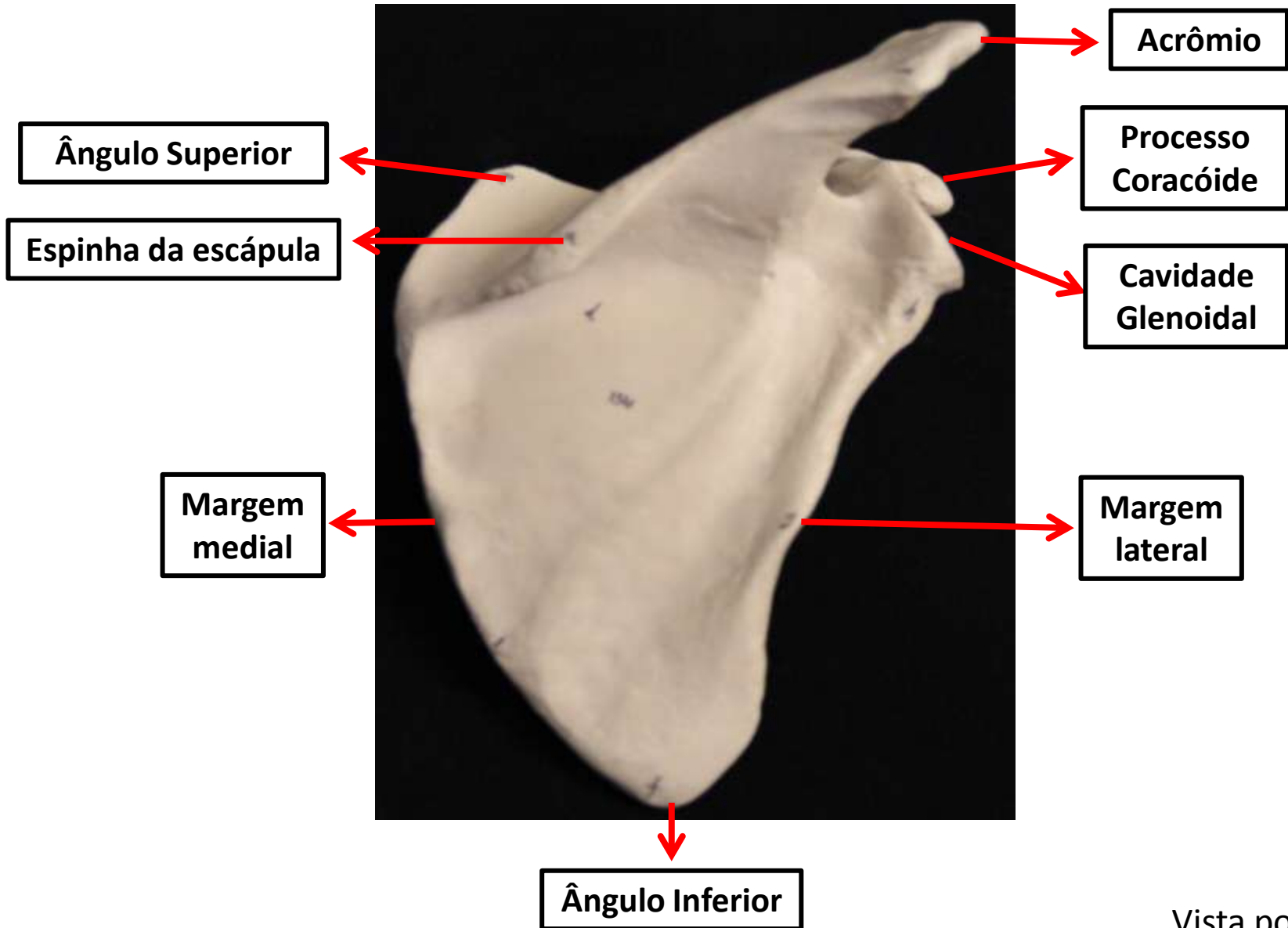
Extremidade esternal -
articular com o esterno

Extremidade acromial -
articular com a escápula



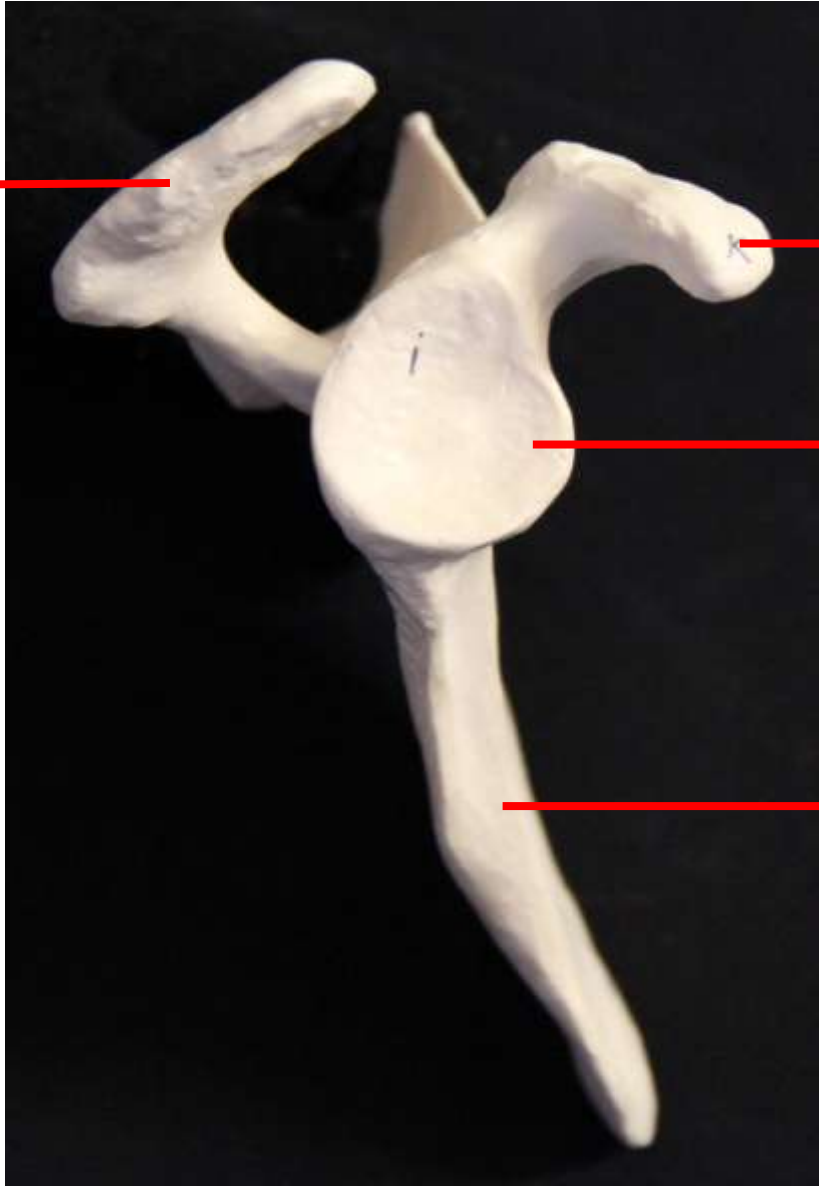
Clavícula – Vista inferior

Escápula



Vista posterior

Acrômio



**Processo
Coracóide**

**Cavidade
Glenoidal**

**Marge
m
lateral**

Escápula – Vista lateral

Ângulo Superior

Acrômio

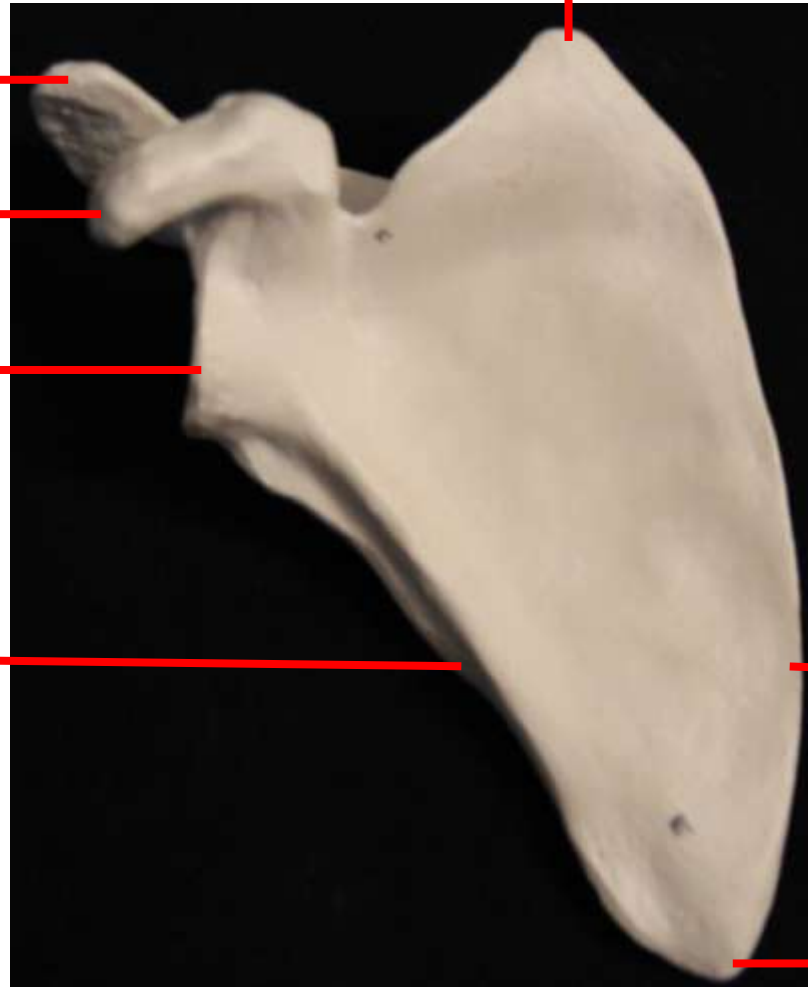
Processo
Coracóide

Cavidade
Glenoidal

Margem
lateral

Margem
medial

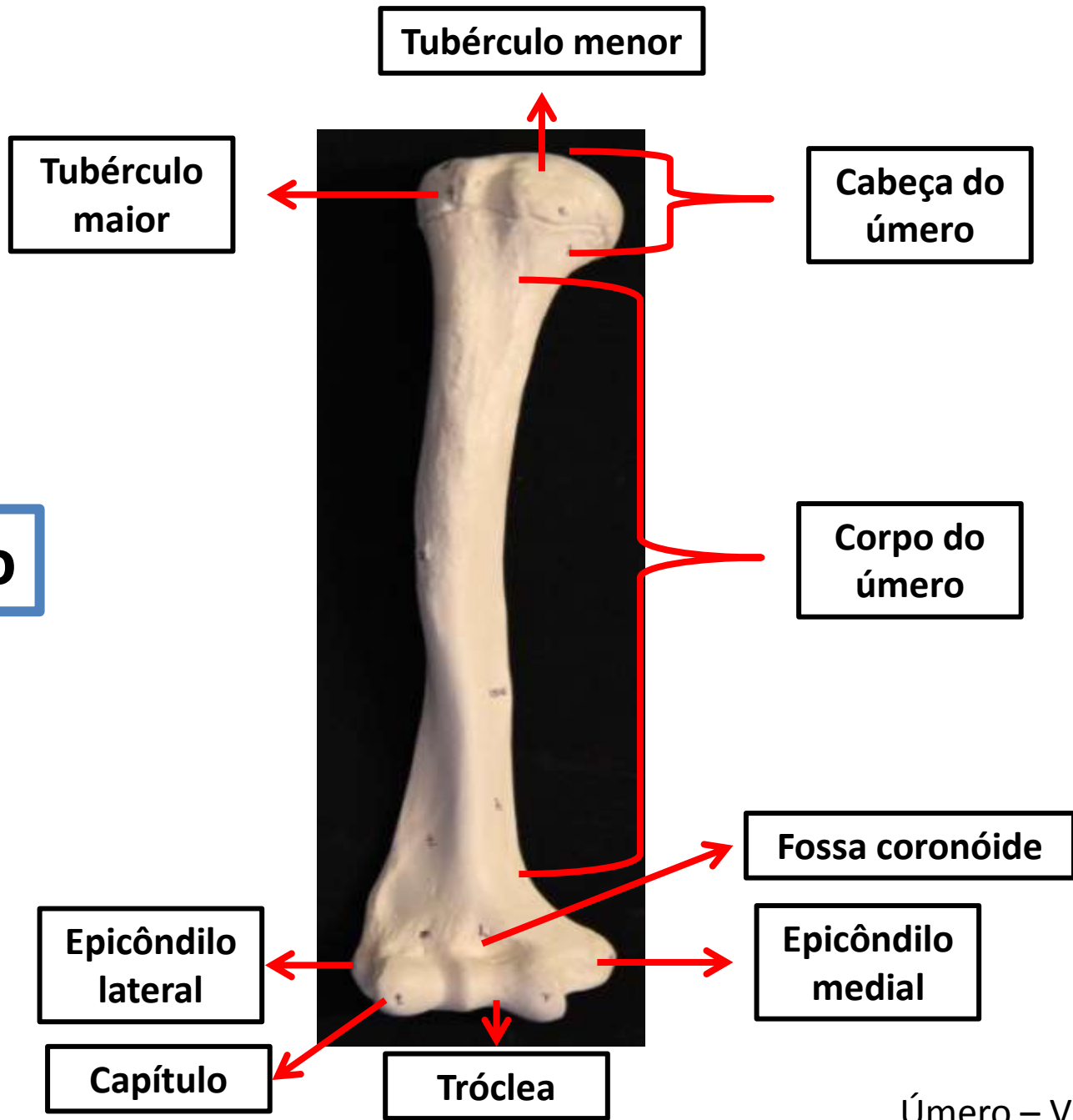
Ângulo Inferior



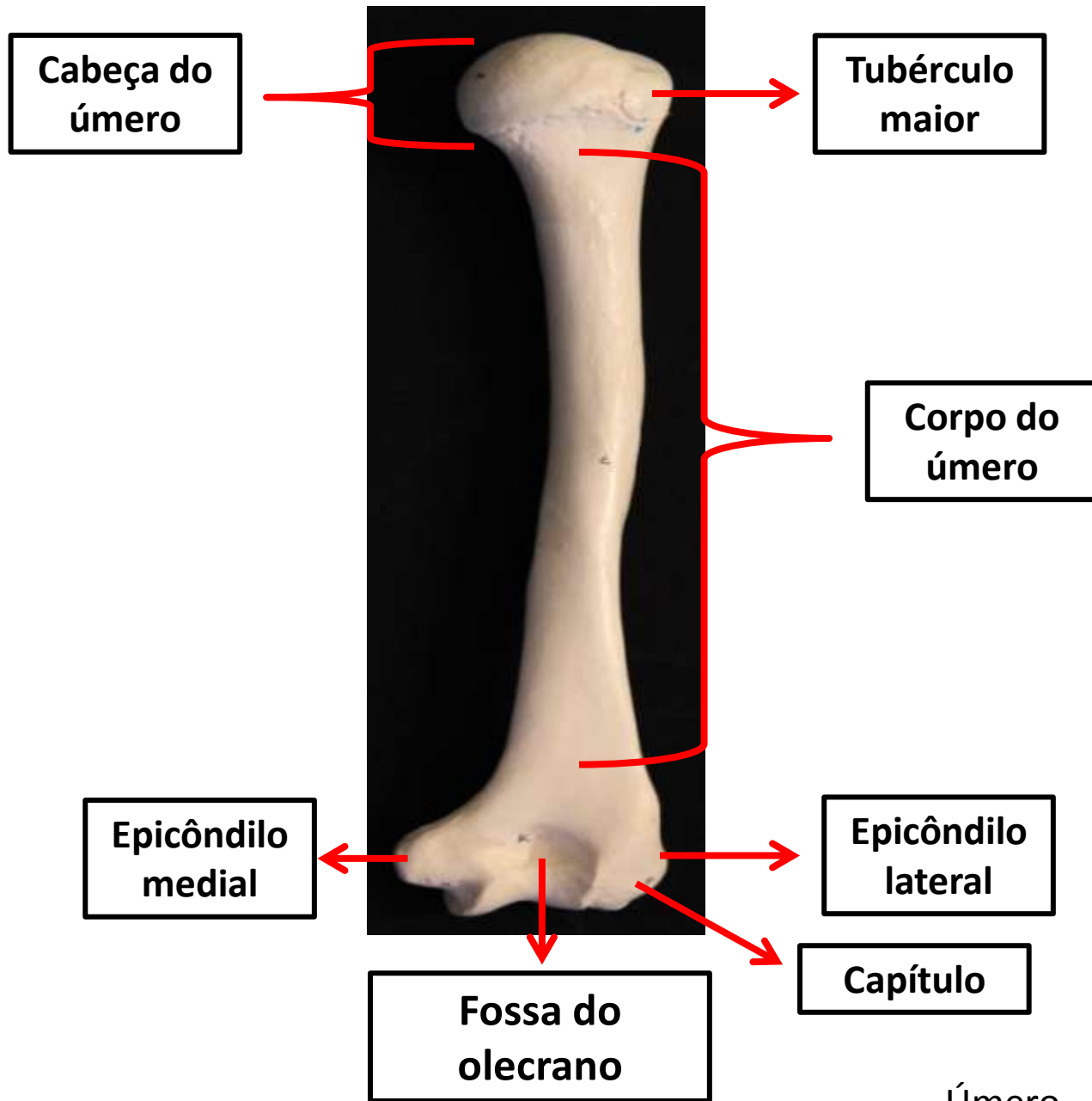
Escápula – Vista anterior

Ossos do Membro Superior

Úmero



Úmero – Vista anterior

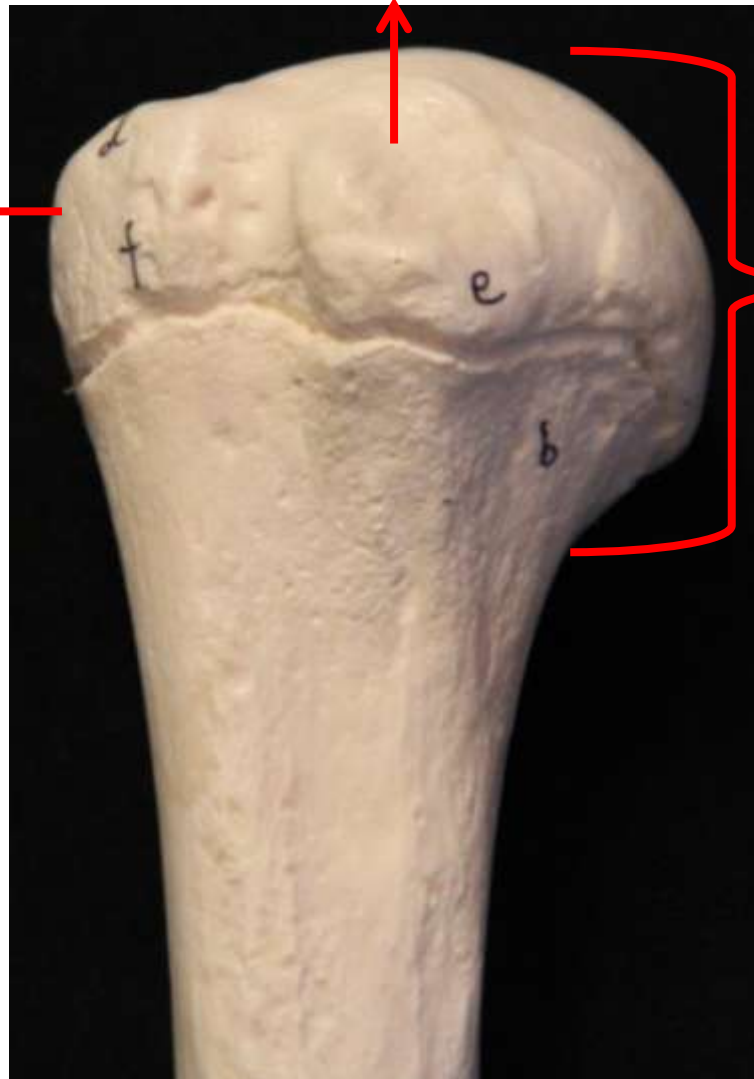


Úmero – Vista posterior

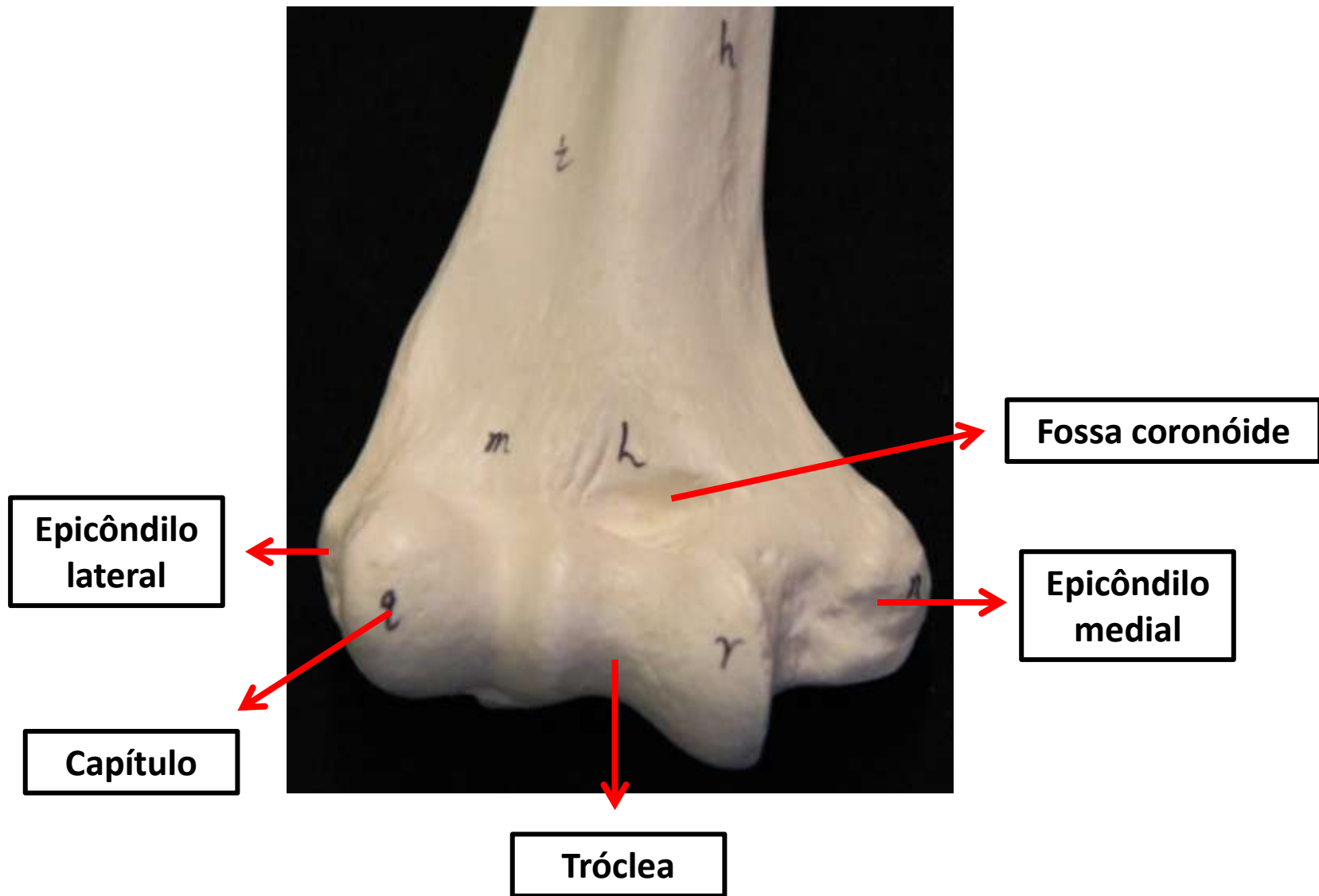
Tubérculo
menor

Tubérculo
maior

Cabeça do
úmero



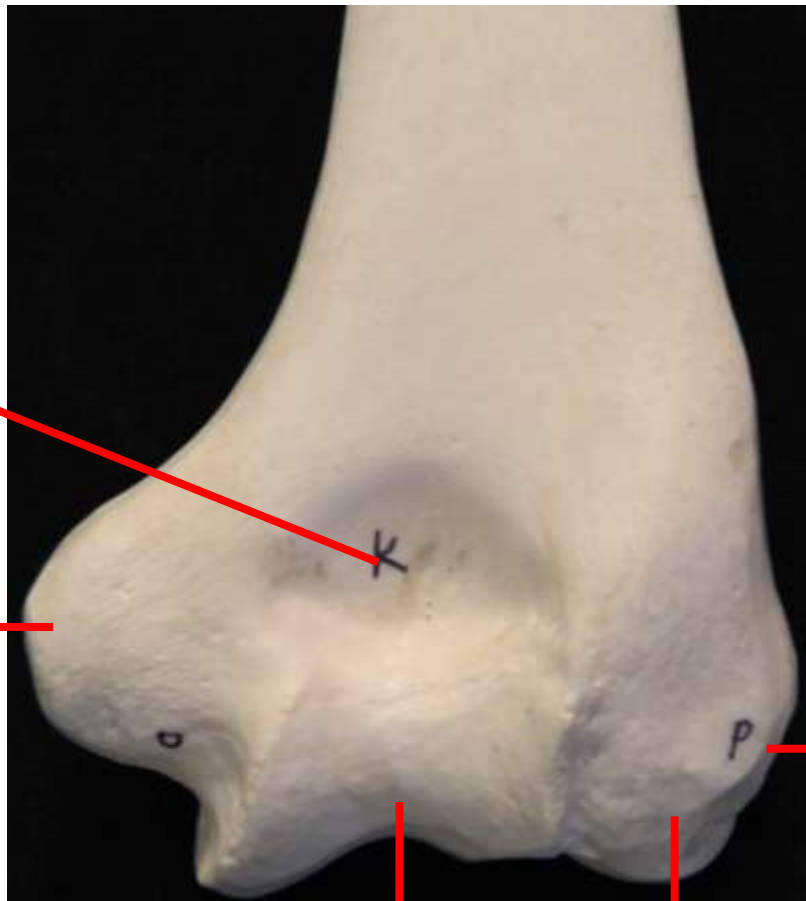
Úmero – Vista anterior
Porção proximal



Úmero – Vista anterior
Porção distal

Fossa do olécrano

Epicôndilo
medial



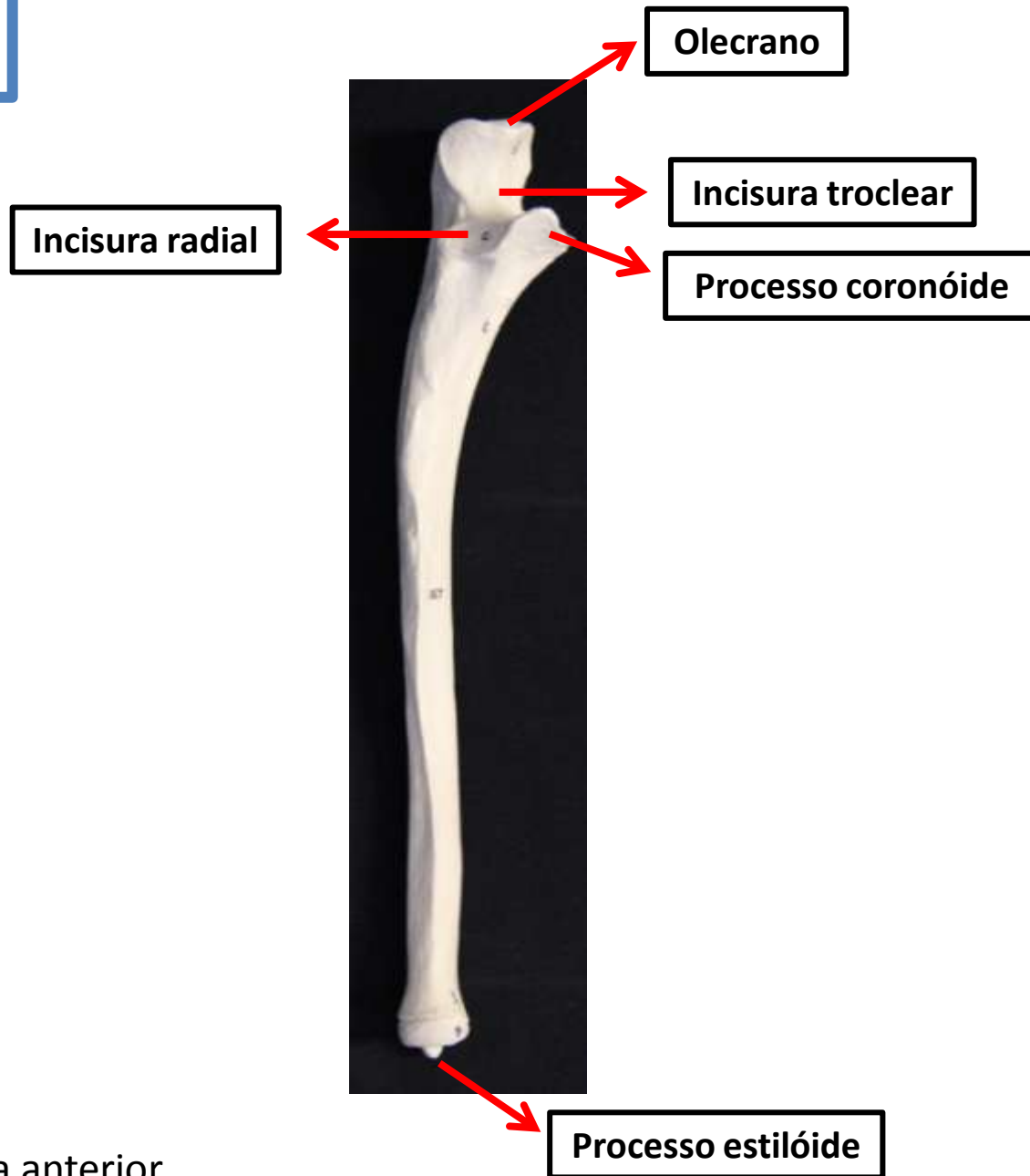
Epicôndilo
lateral

Tróclea

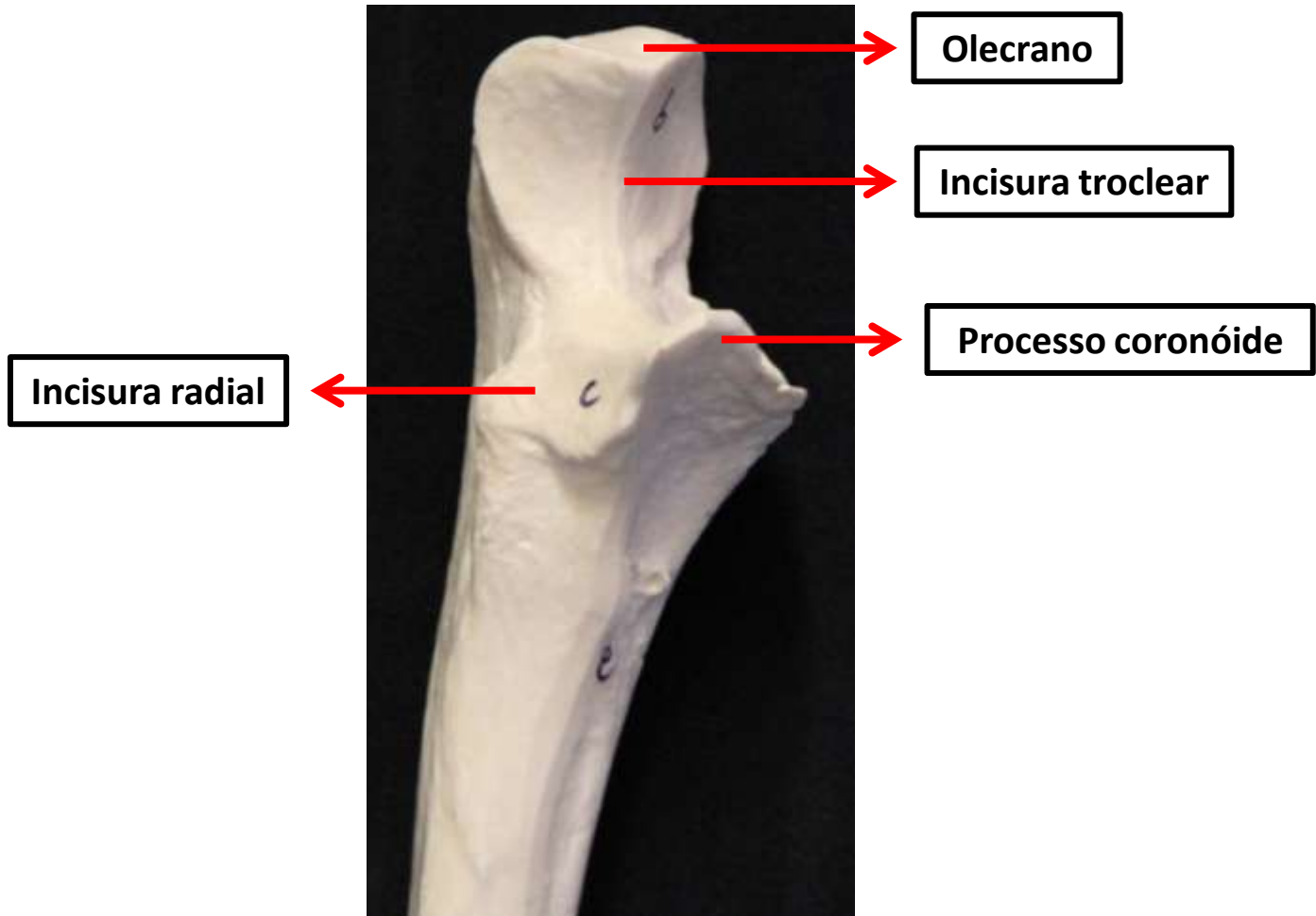
Capítulo

Úmero – Vista posterior
Porção distal

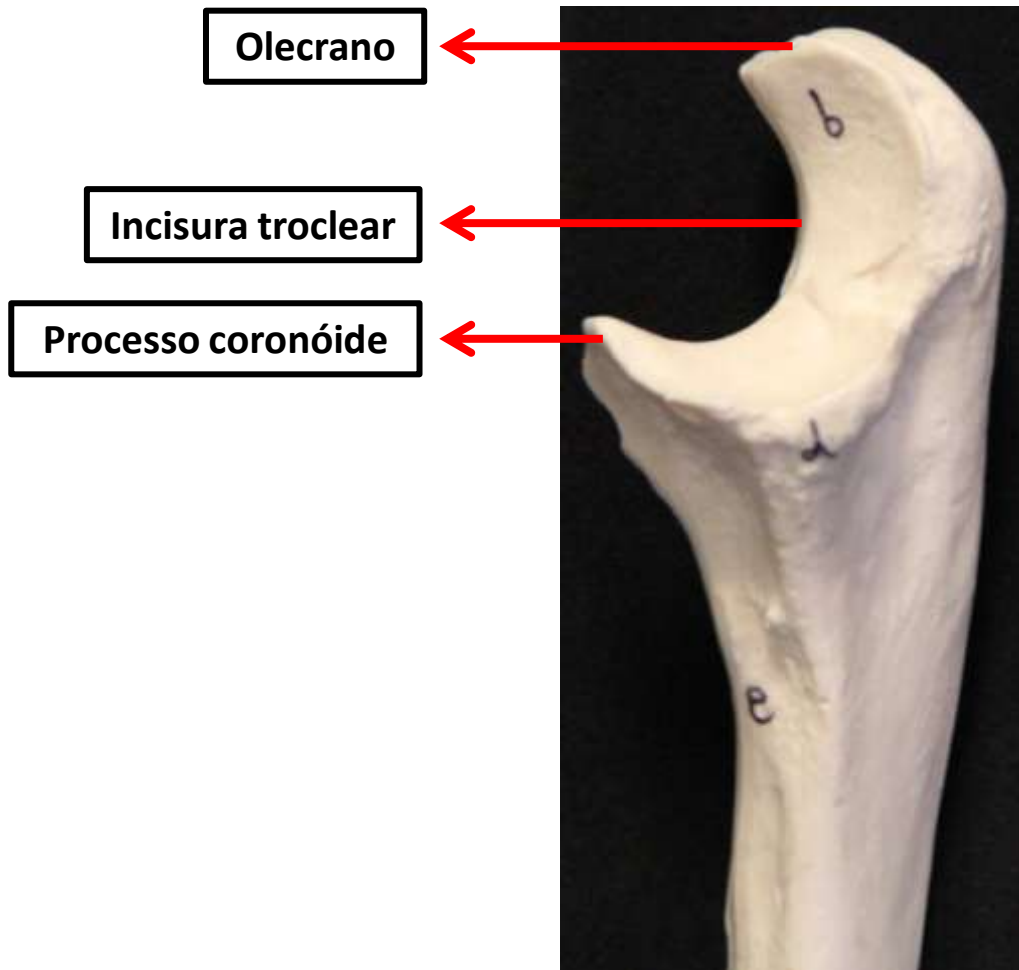
Ulna



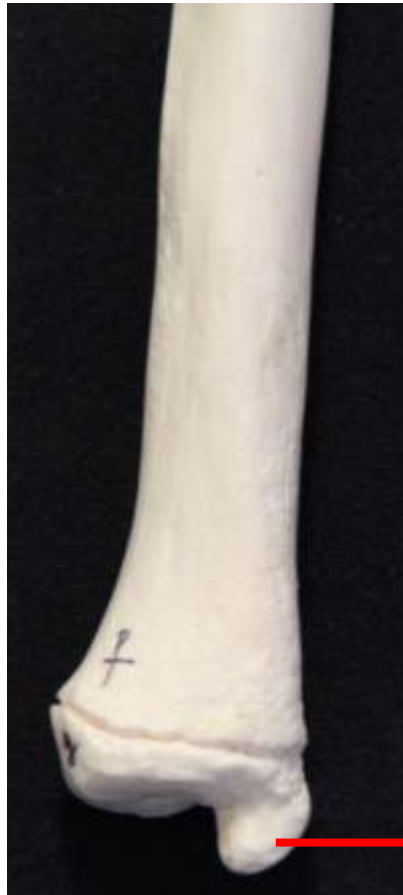Ulna – Vista anterior



Ulna – Vista anterior
Porção Proximal



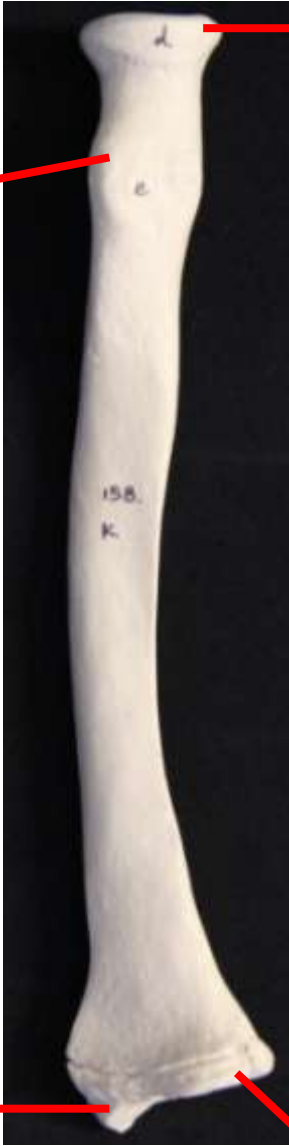Ulna – Vista lateral
Porção Proximal



Processus estilóide

Ulna – Vista anterior
Porção Proximal

Rádio



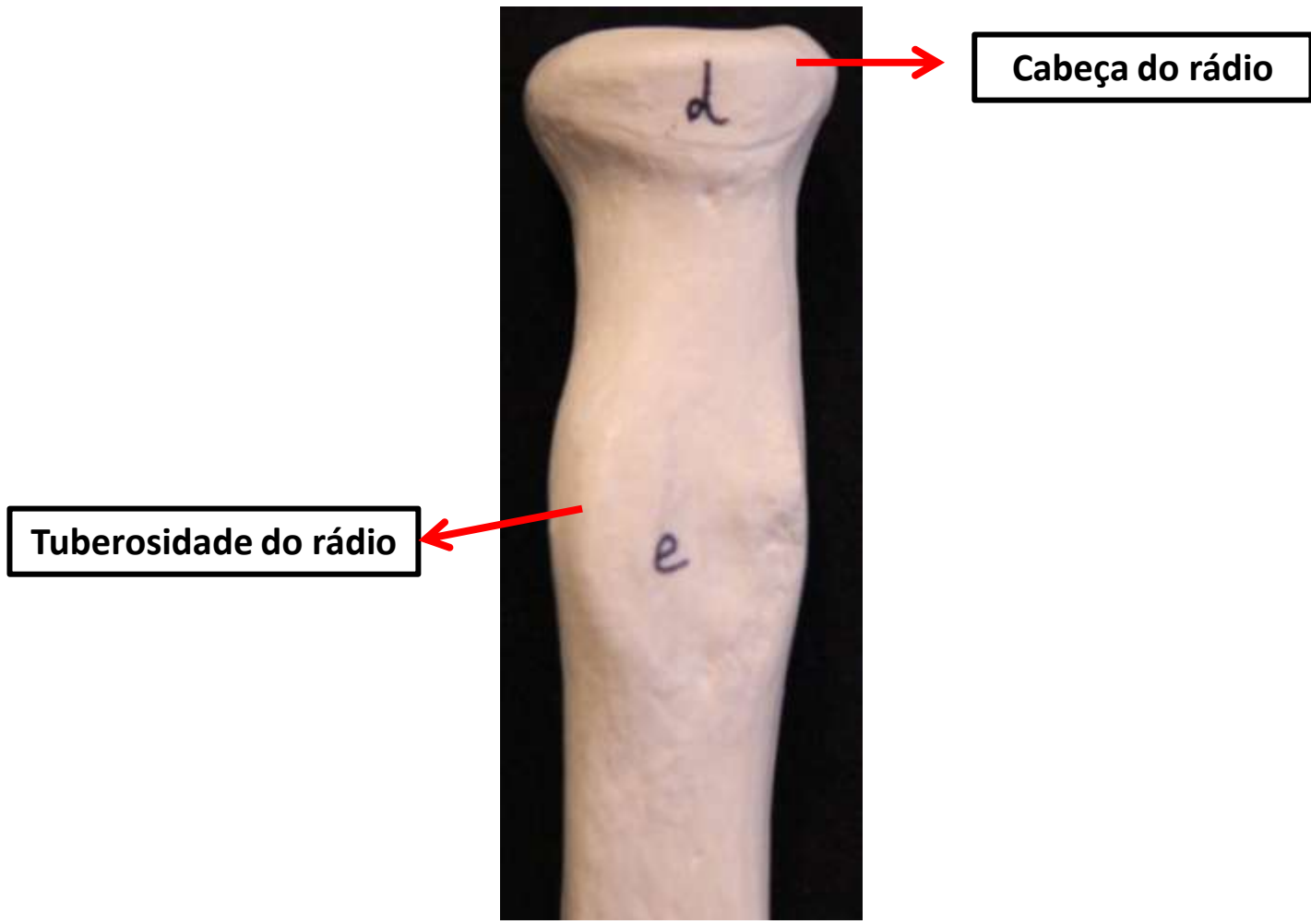
Cabeça do rádio

Tuberosidade do rádio

Processo estilóide

Face articular carpal

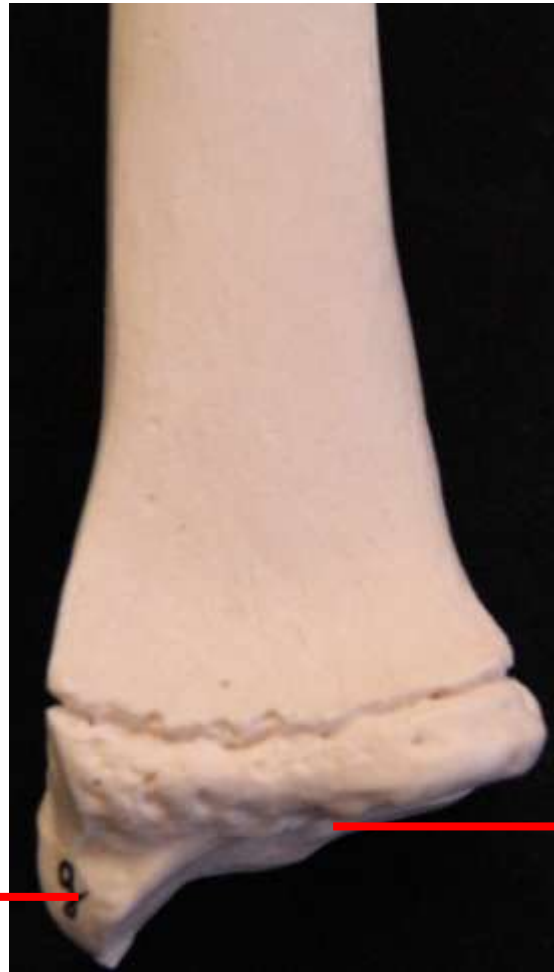Rádio – Vista anterior



Cabeça do rádio

Tuberosidade do rádio

Rádio – Vista anterior
Porção Proximal



Processo estilóide

Face articular carpal

Rádio – Vista anterior
Porção distal

Mão

Ossos do Carpo

Metacarpo
(I a V)

Mínimo

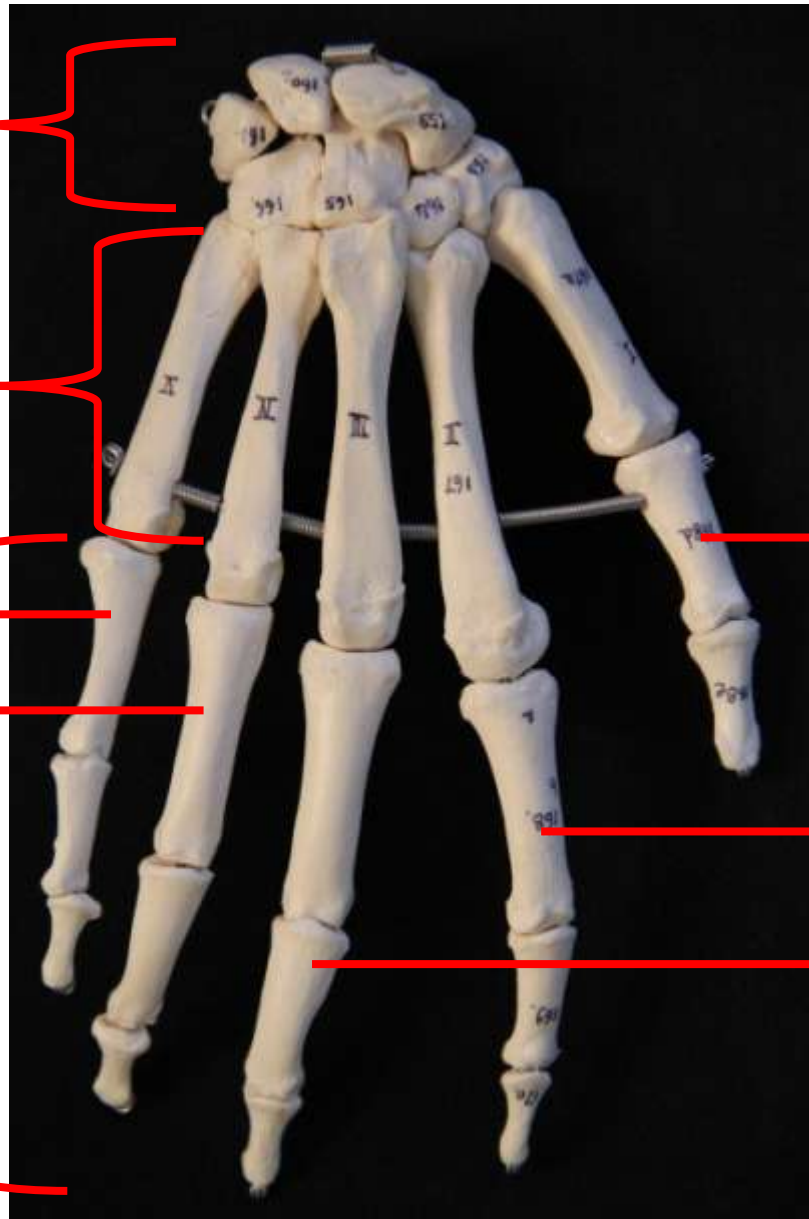
Anular

Falanges

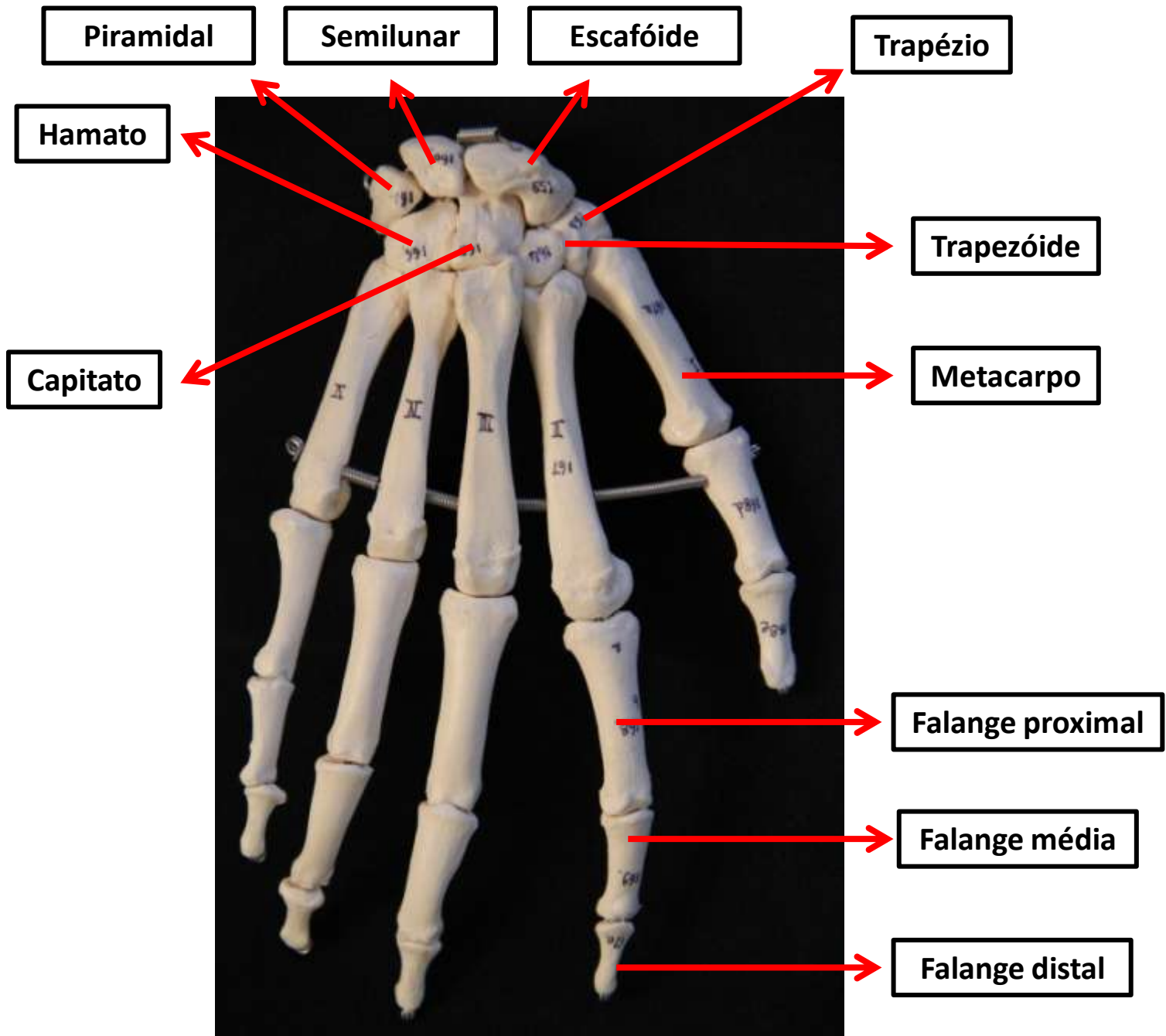
Polegar

Indicador

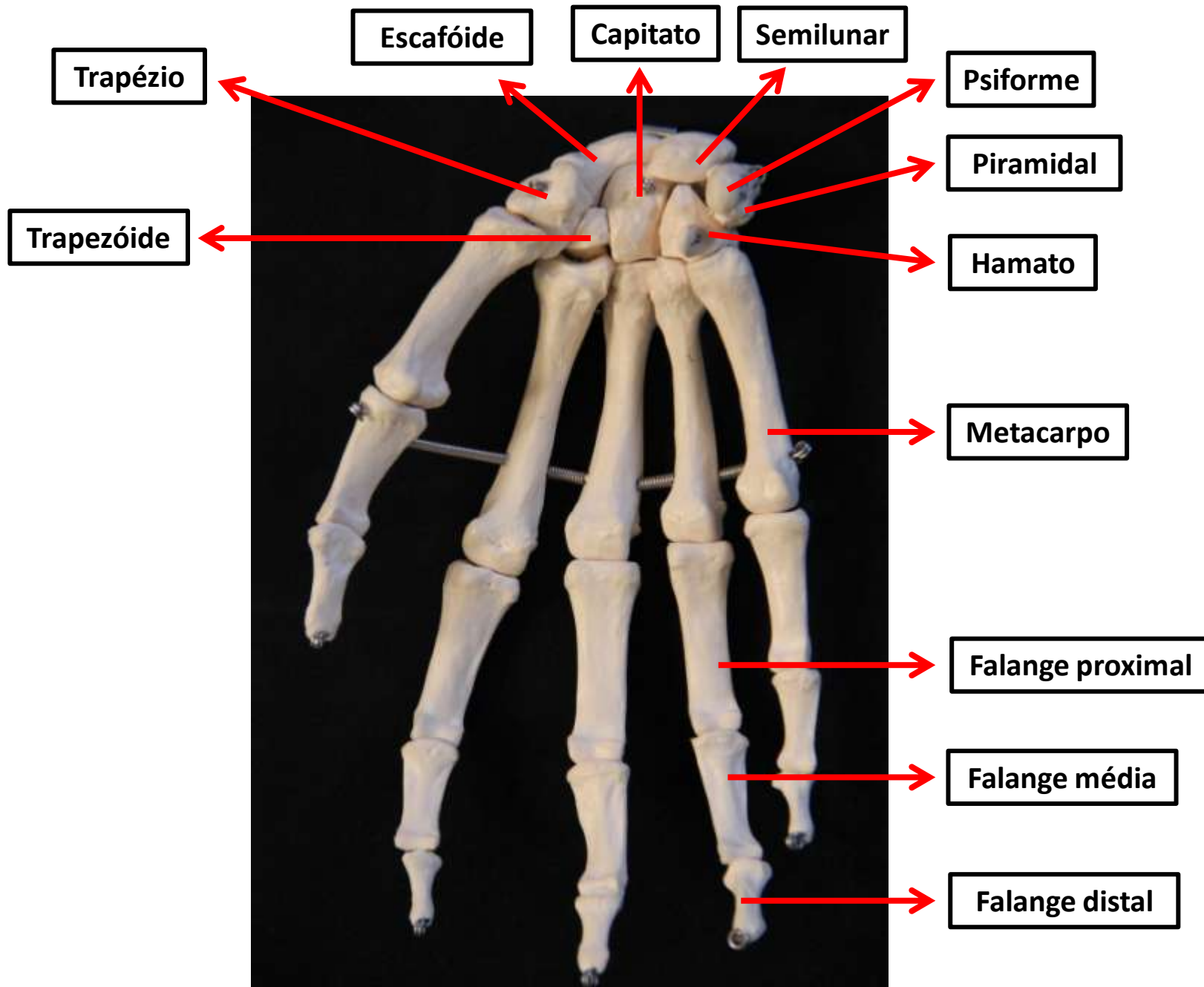
Dedo
médio



Mão Direita– Vista anterior

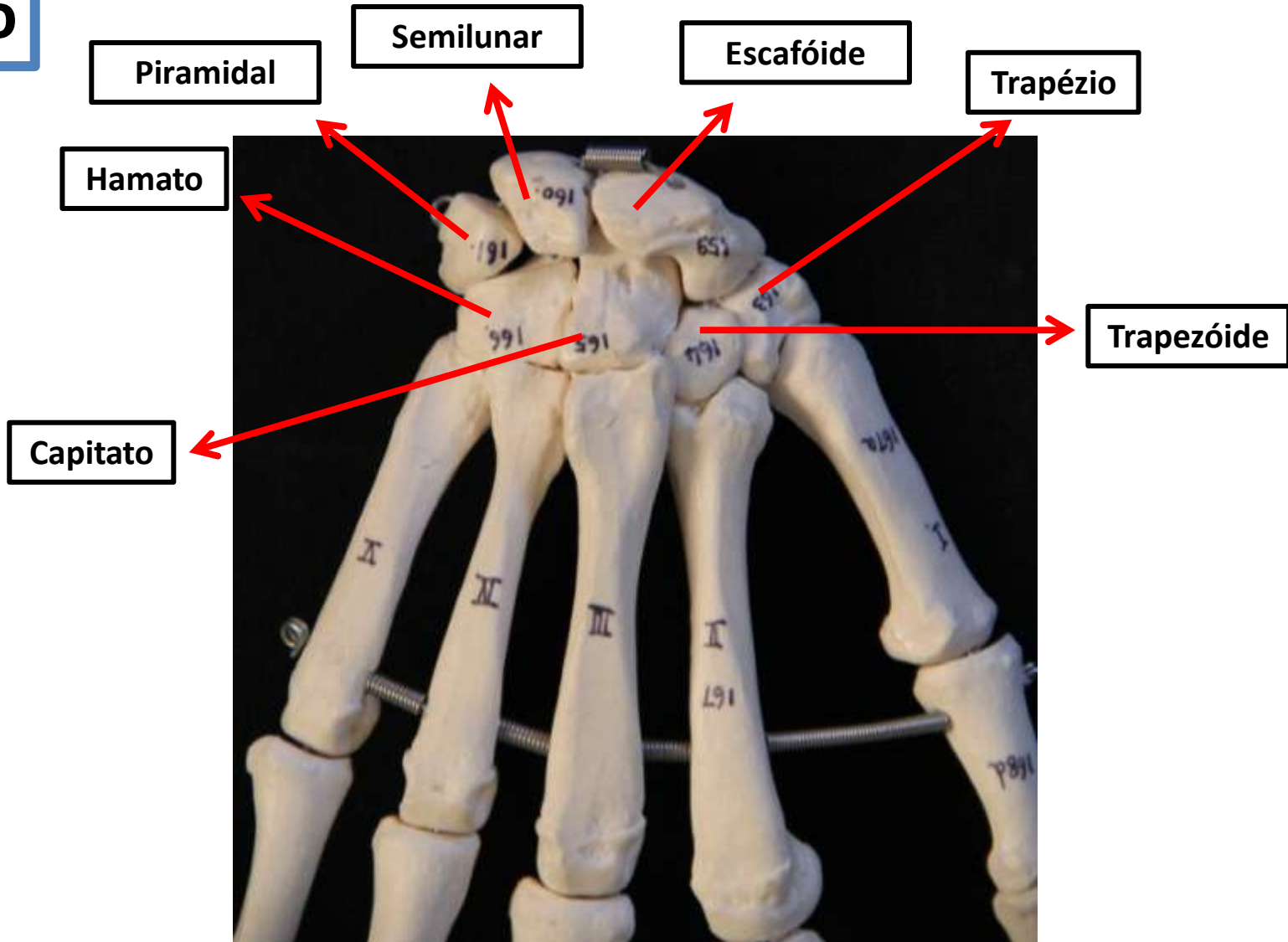


Mão Direita- Vista posterior



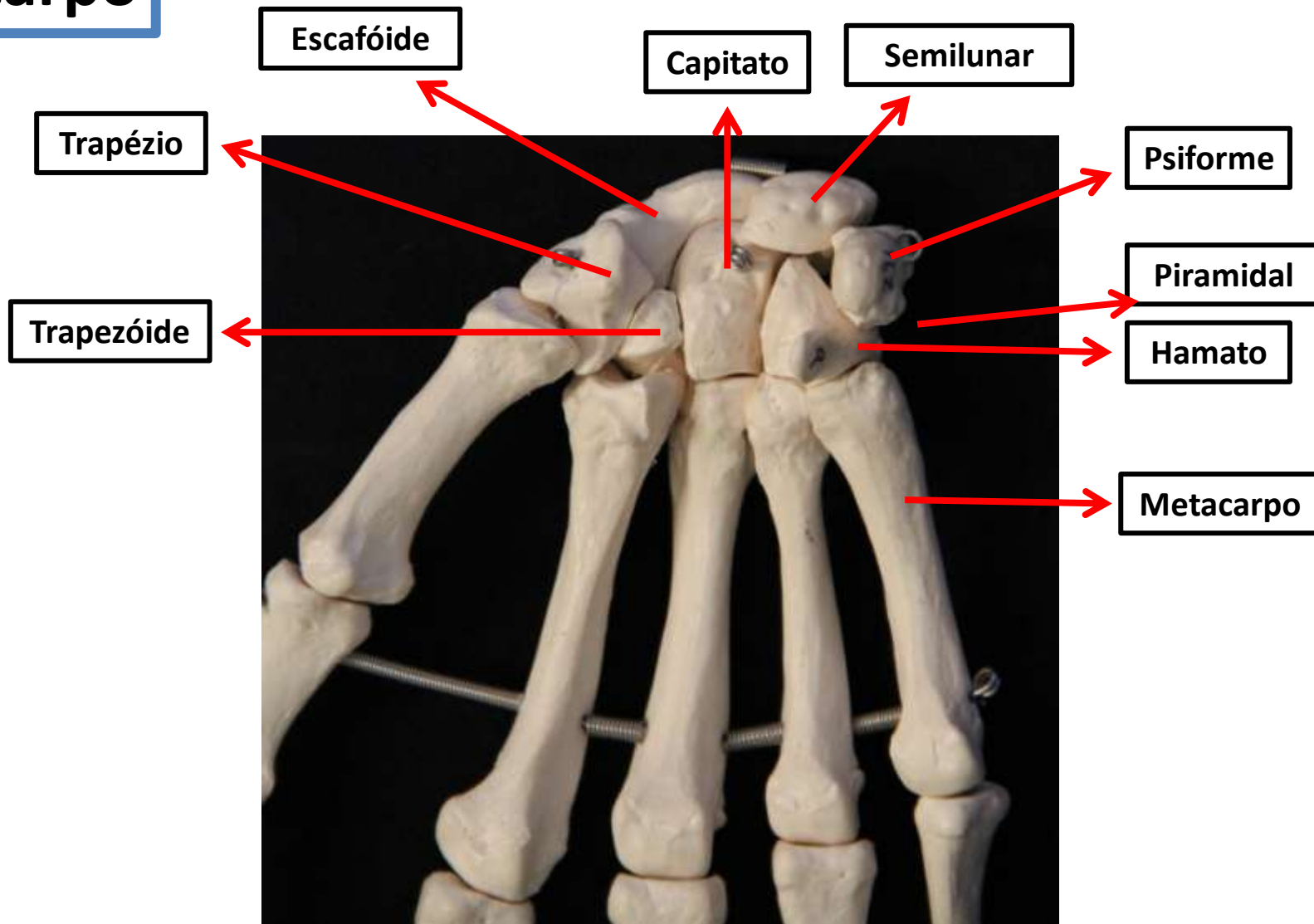
Mão Direita- Vista anterior

Ossos do carpo



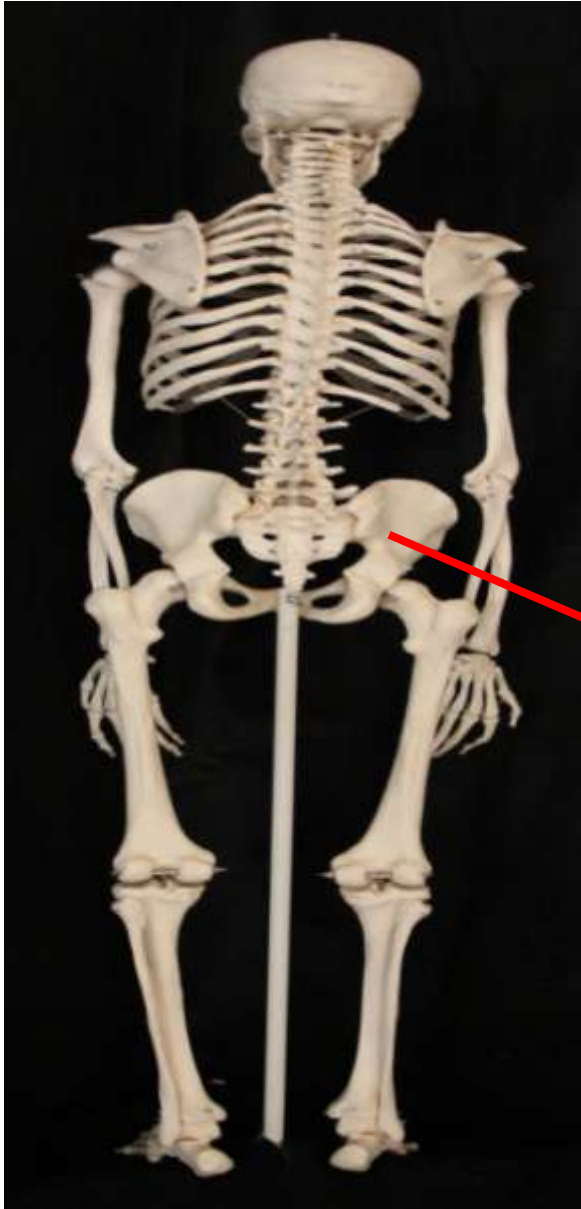Mão Direita– Vista anterior

Ossos do carpo

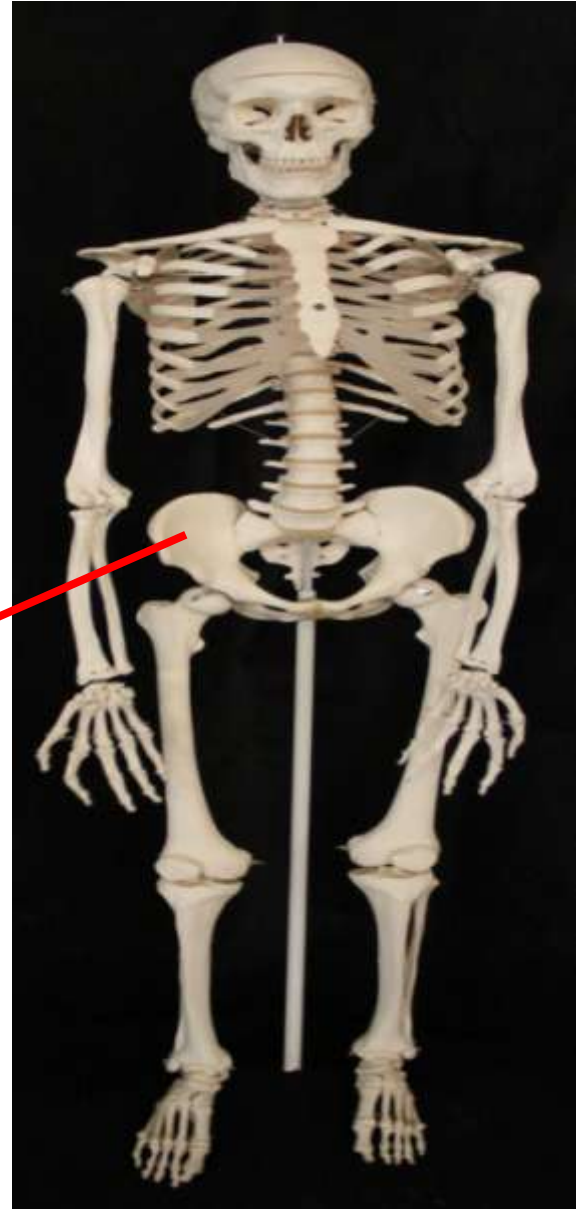


Mão Direita– Vista posterior

*Ossos do Cíngulo
do Membro
Inferior*



Ossos do Quadril



Ossos do Quadril

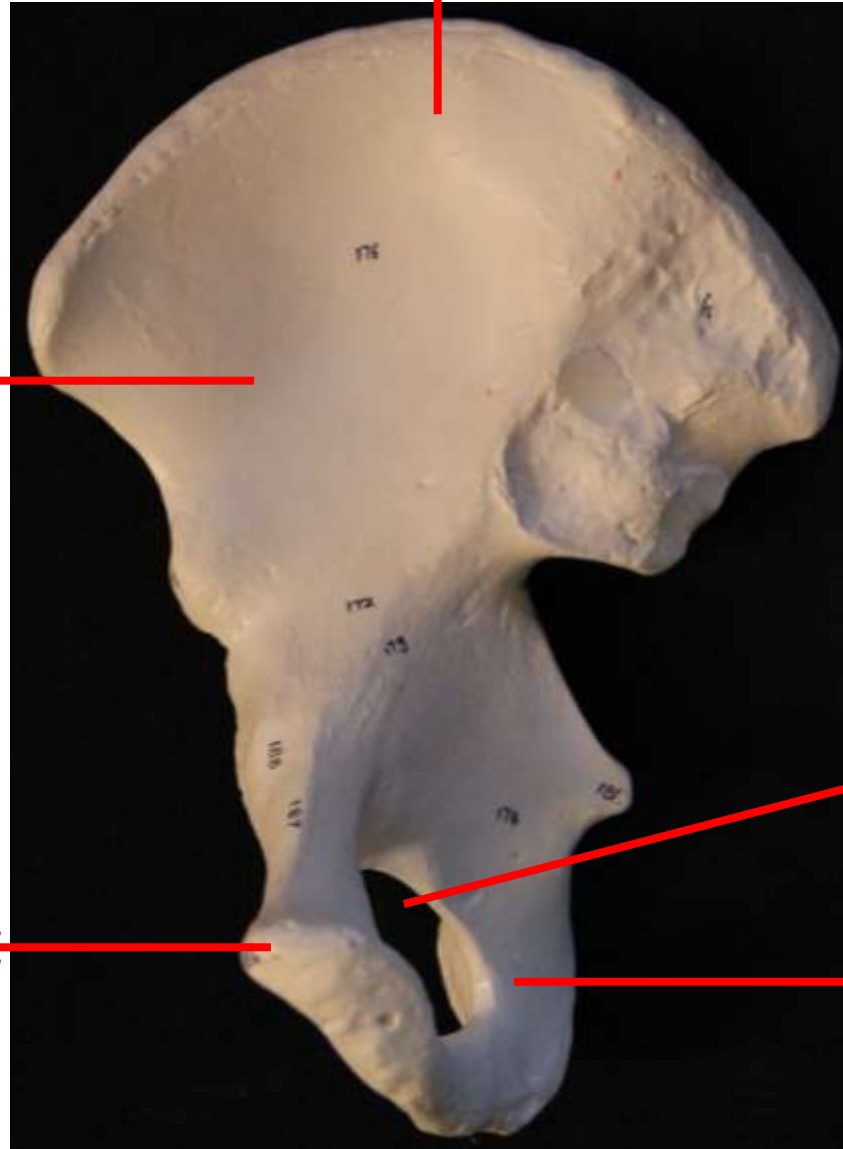
Ílio

Fossa íliaca

Púbis

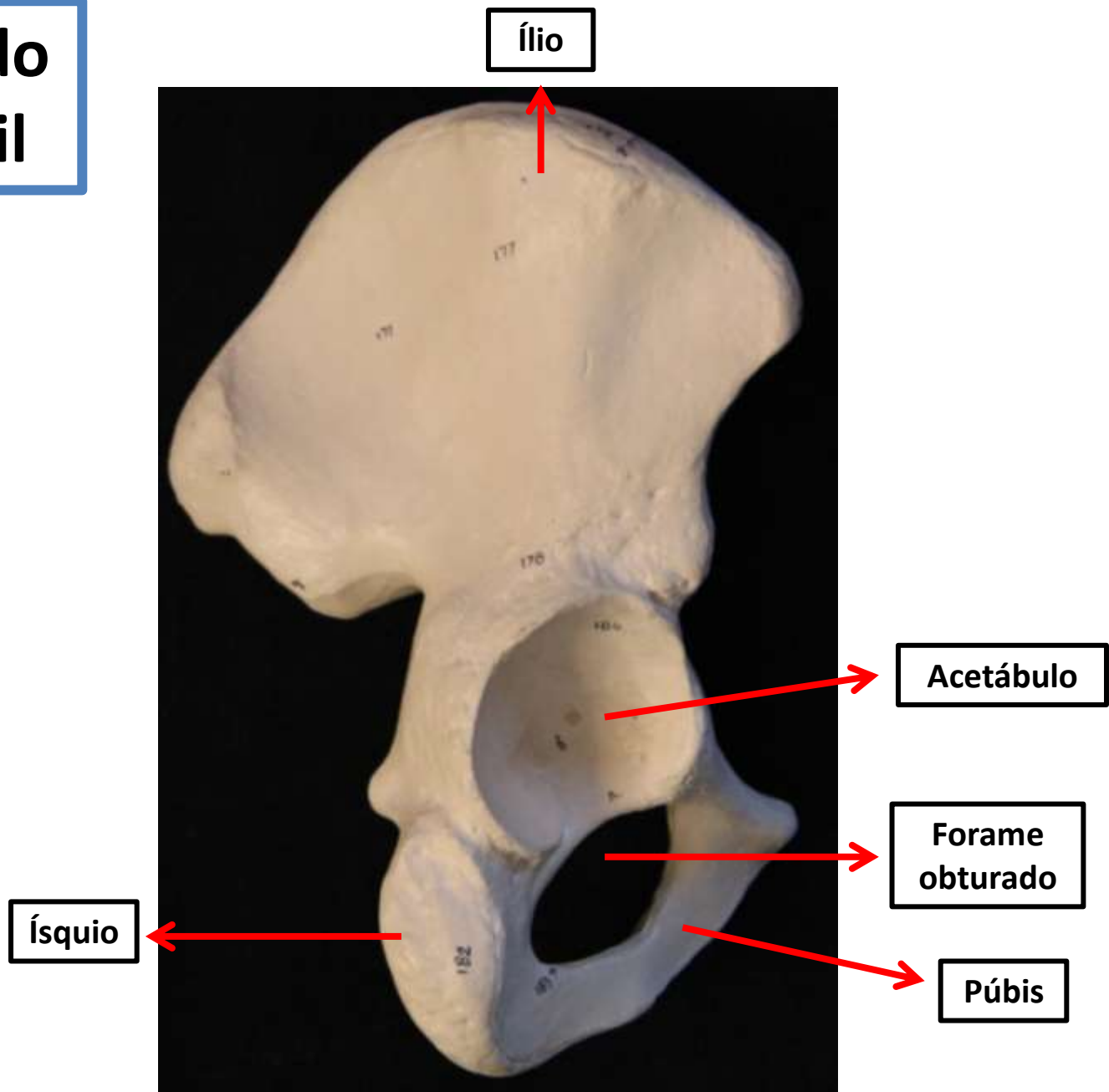
Forame obturado

Ísquio



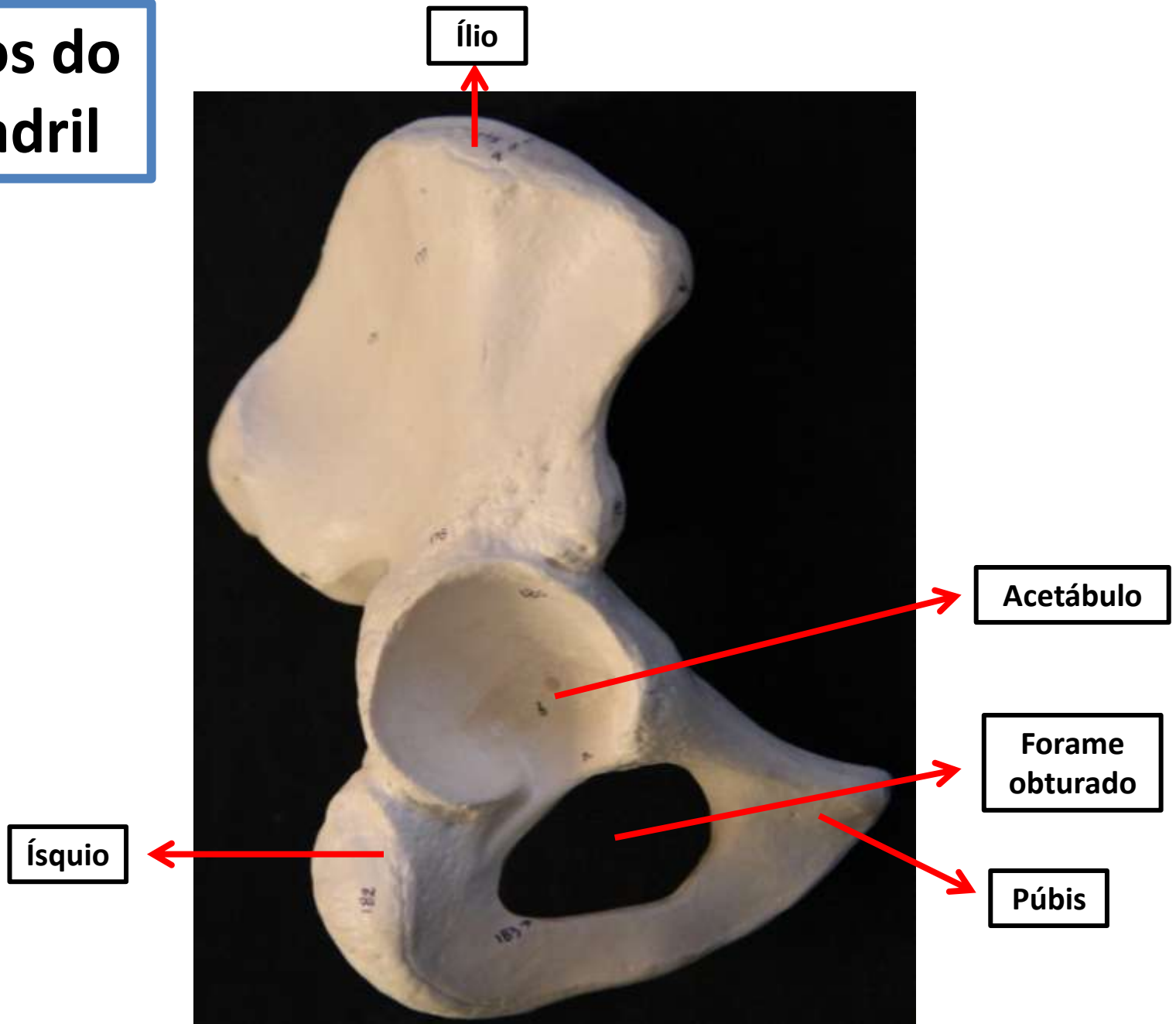
Ossos do quadril- Vista anterior

Ossos do Quadril

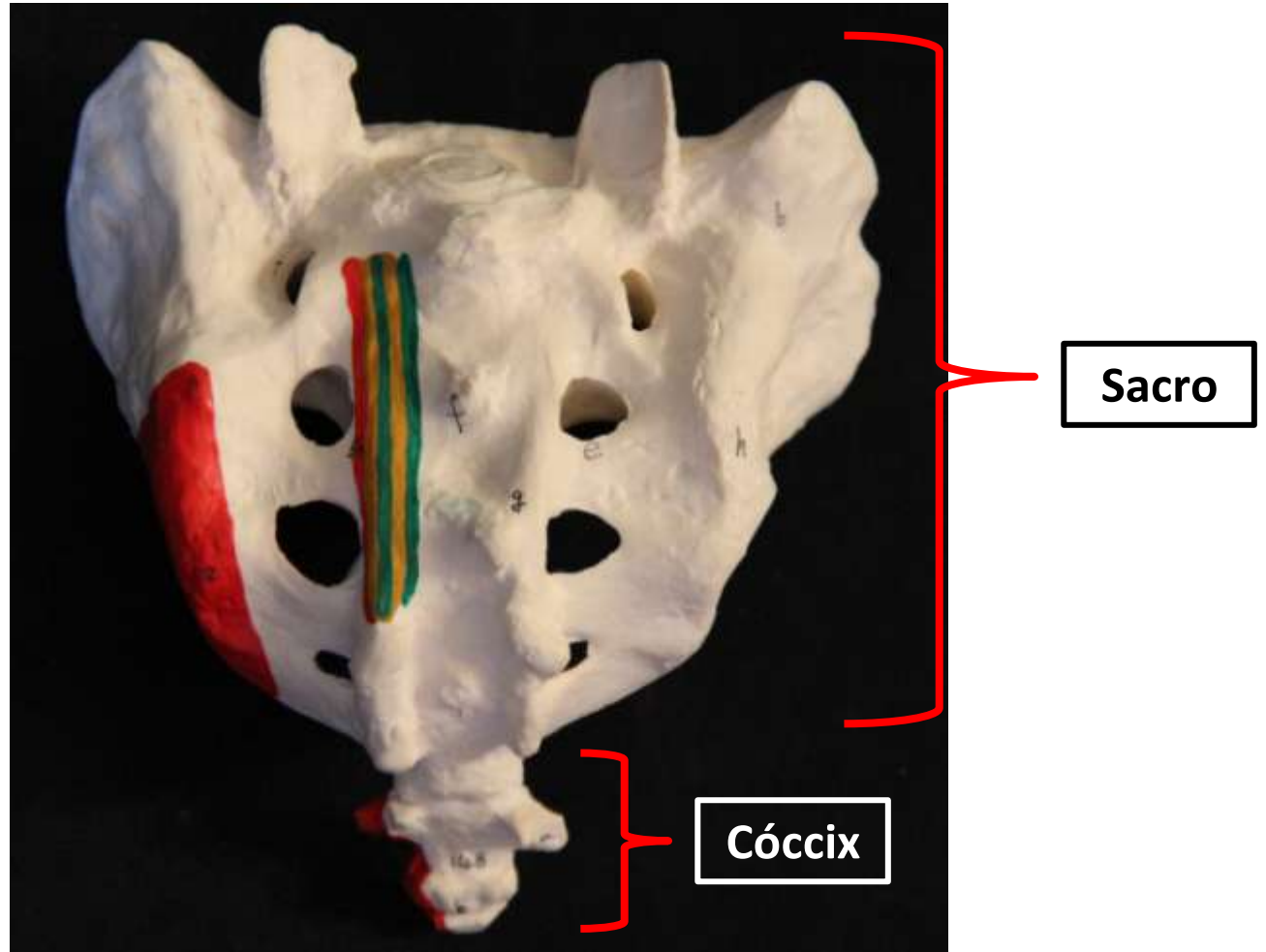


Ossos do quadril– Vista posterior

Ossos do Quadril



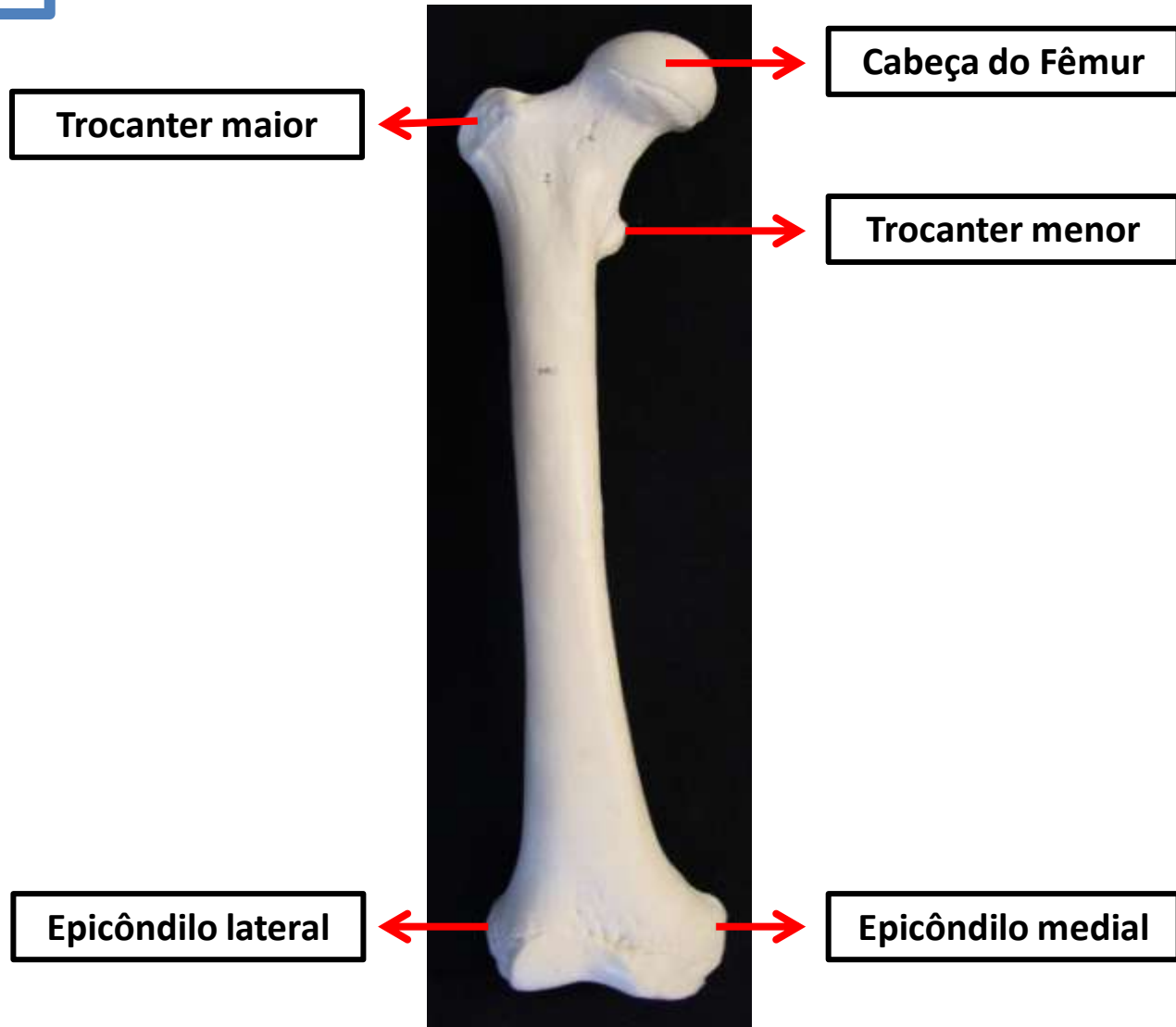
Ossos do quadril– Vista lateral



Vista Posterior

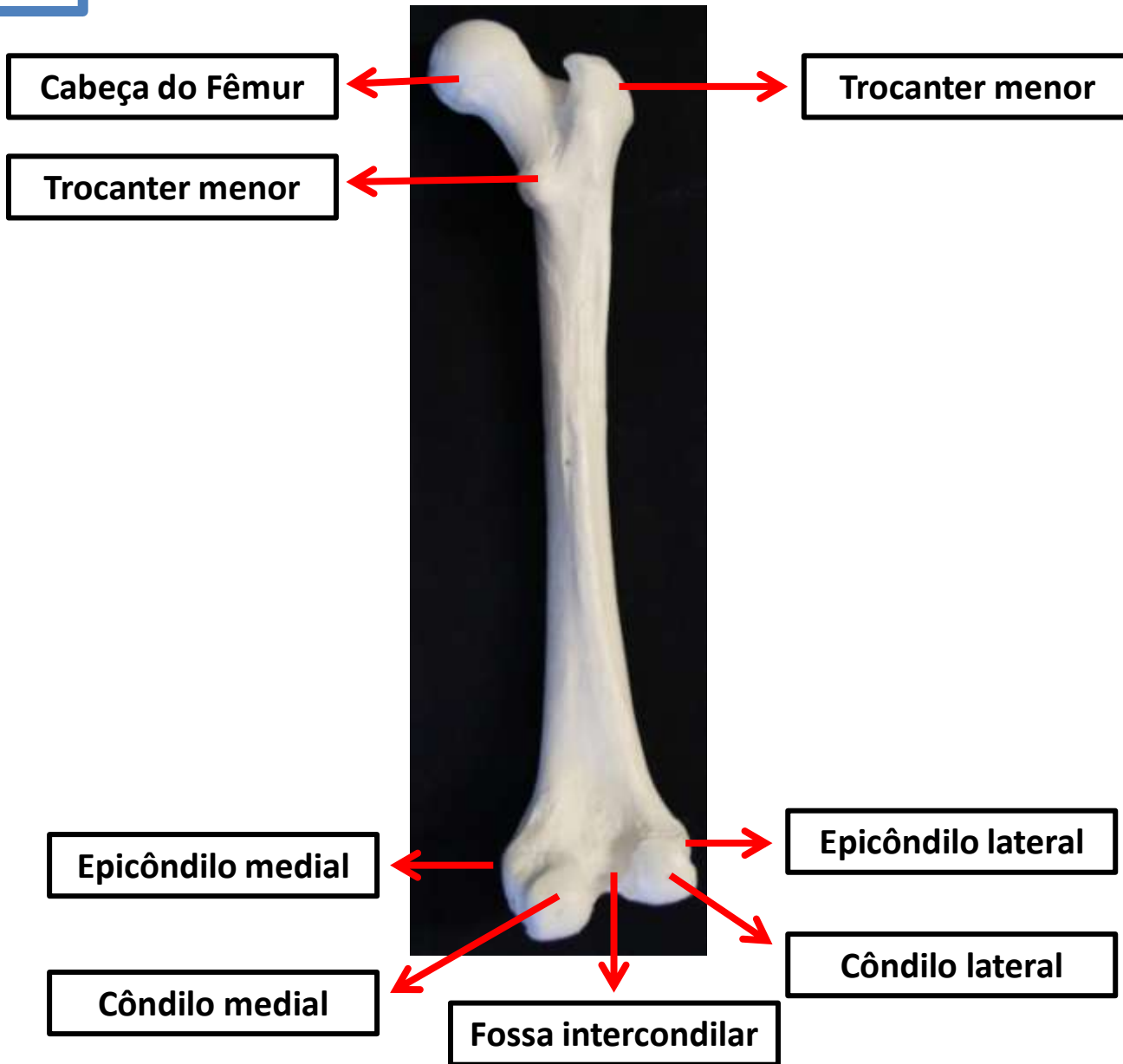
Ossos do Membro Inferior

Fêmur

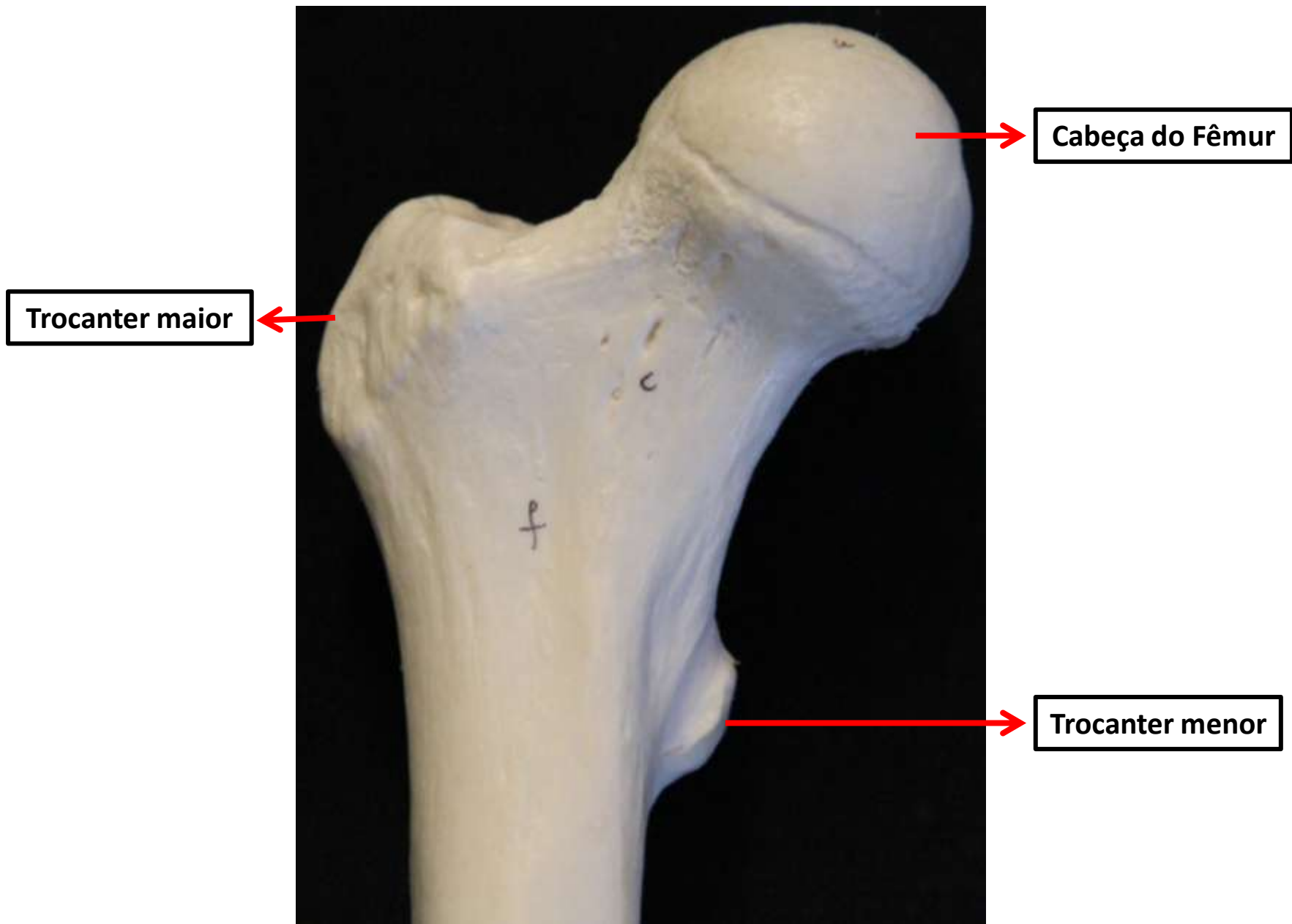


Fêmur – Vista anterior

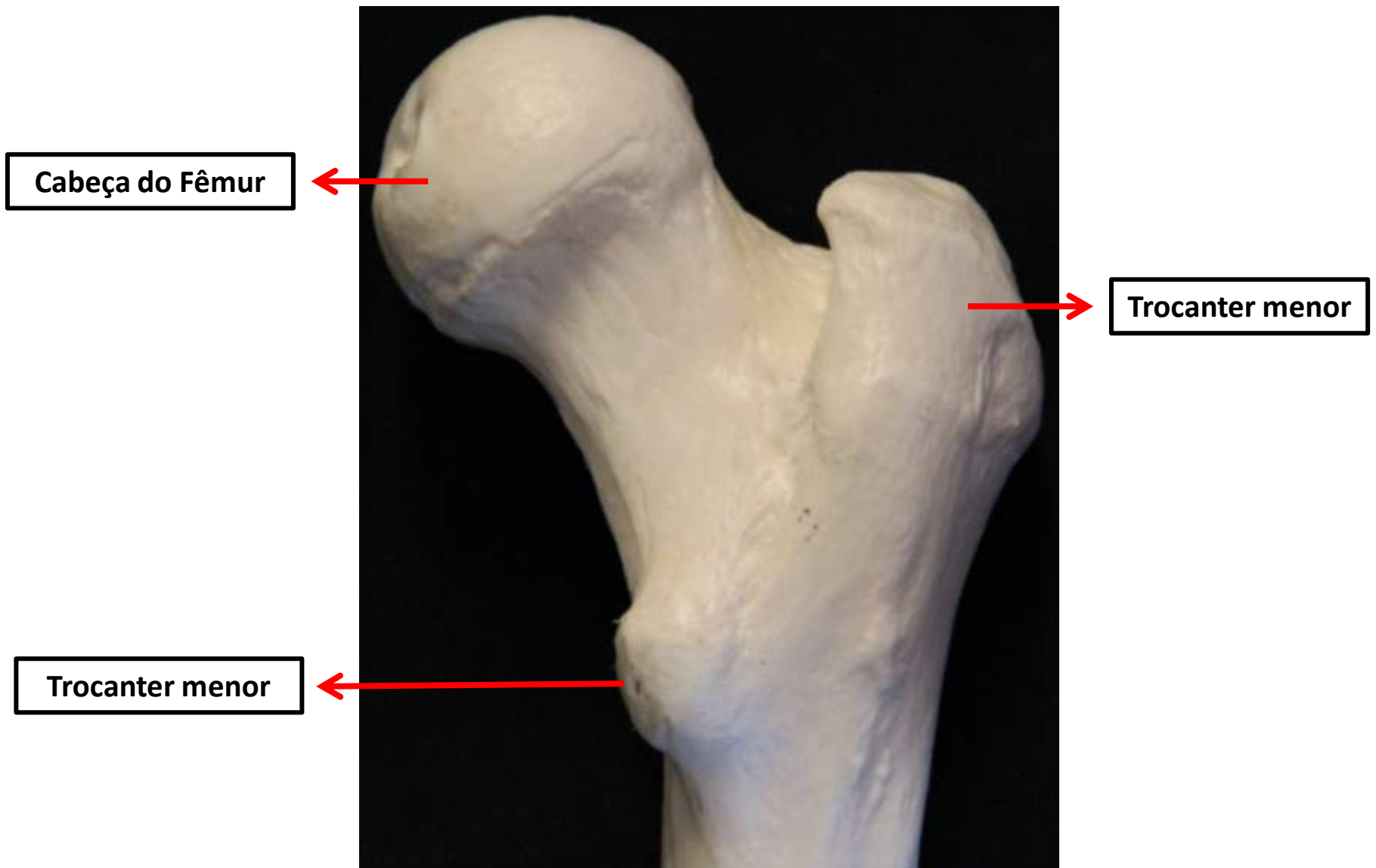
Fêmur



Fêmur – Vista posterior

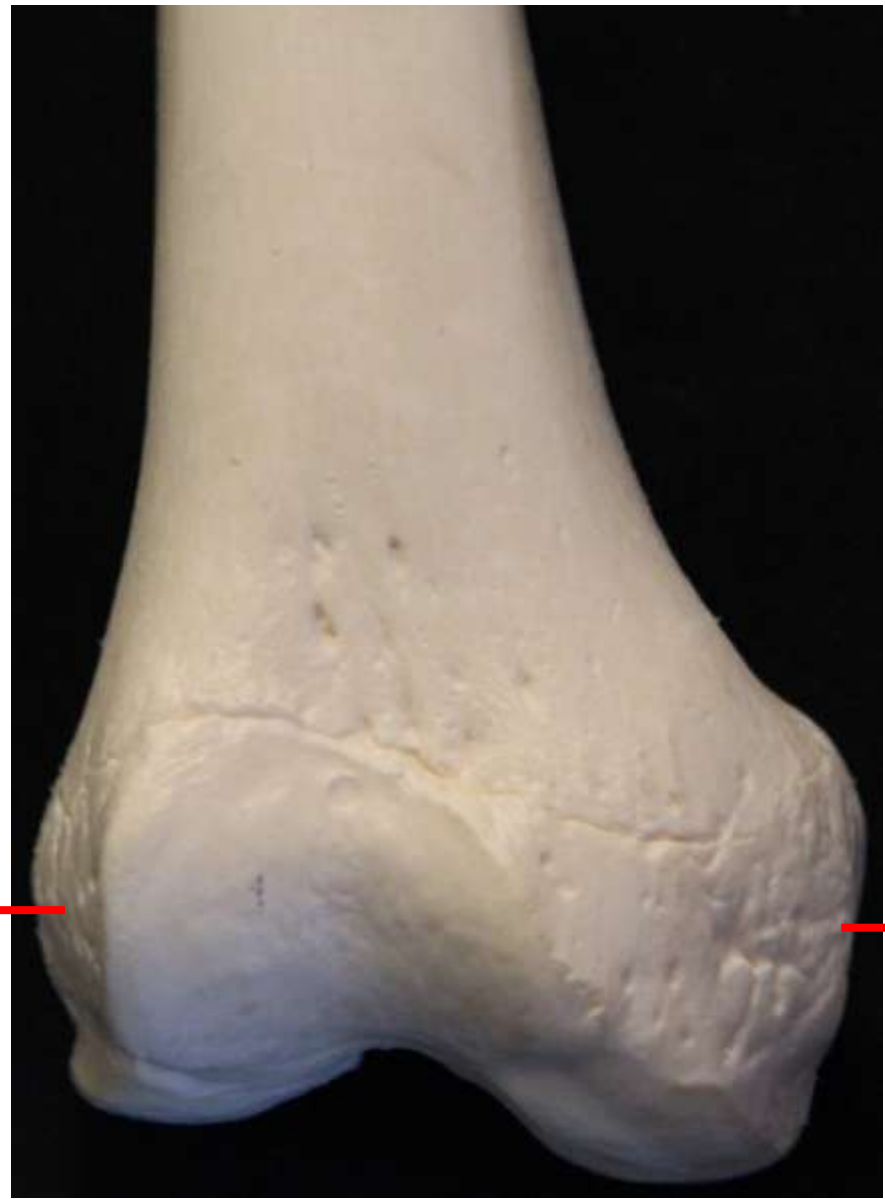

Fêmur (Porção proximal) – Vista anterior



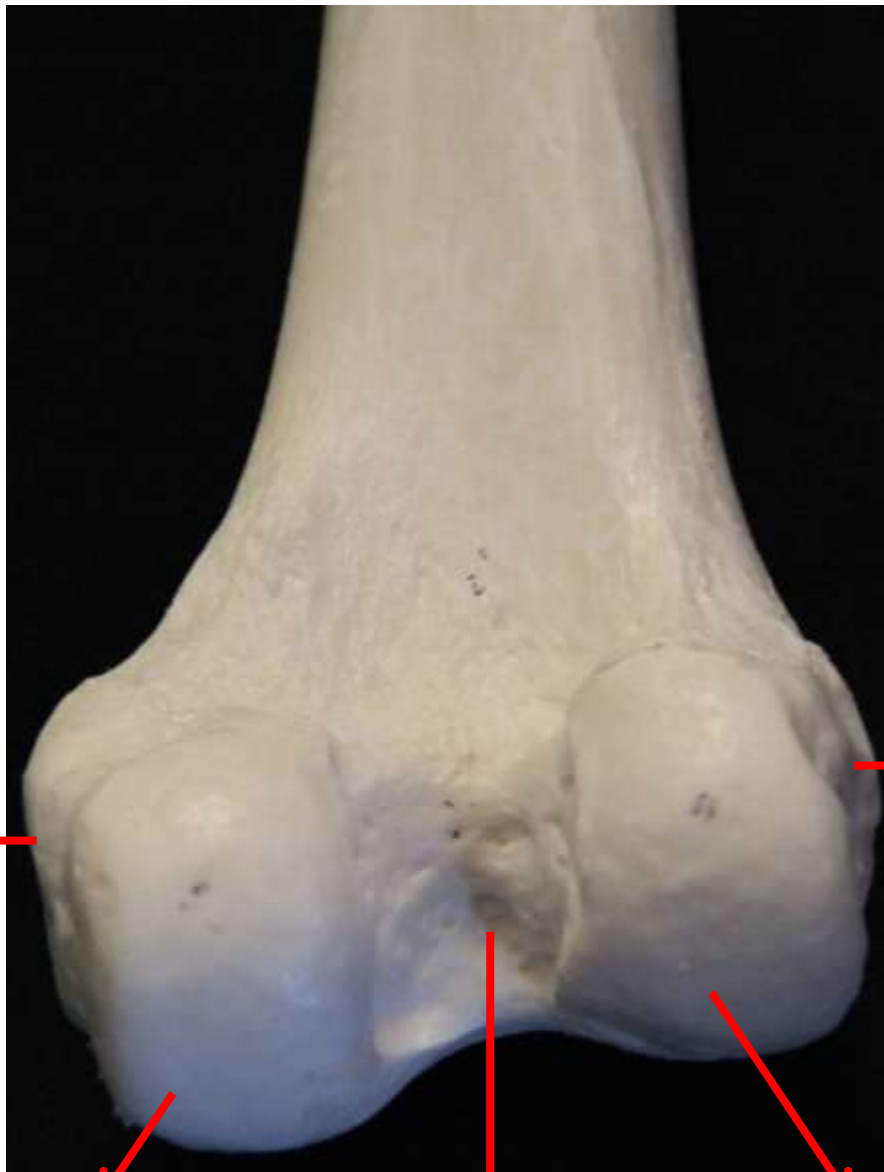Fêmur (Porção proximal) – Vista posterior

Epicôndilo lateral



Epicôndilo medial

Fêmur (Porção distal) – Vista anterior



Epicôndilo medial

Epicôndilo lateral

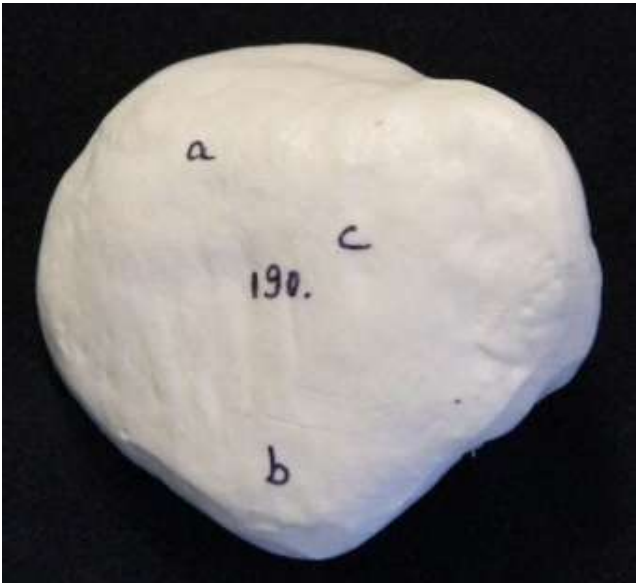
Côndilo medial

Fossa intercondilar

Côndilo lateral

Fêmur (Porção distal) – Vista posterior

Patela



Face anterior (convexa)



Facetas articulares do fêmur
(face posterior côncava)

Tíbia

Face articular superior

Epicôndilo lateral

Epicôndilo medial

Tuberosidade da tíbia



Maléolo medial da tíbia

Face articular inferior

Tíbia – Vista anterior

Tíbia

Face articular superior

Côndilo medial

Côndilo lateral

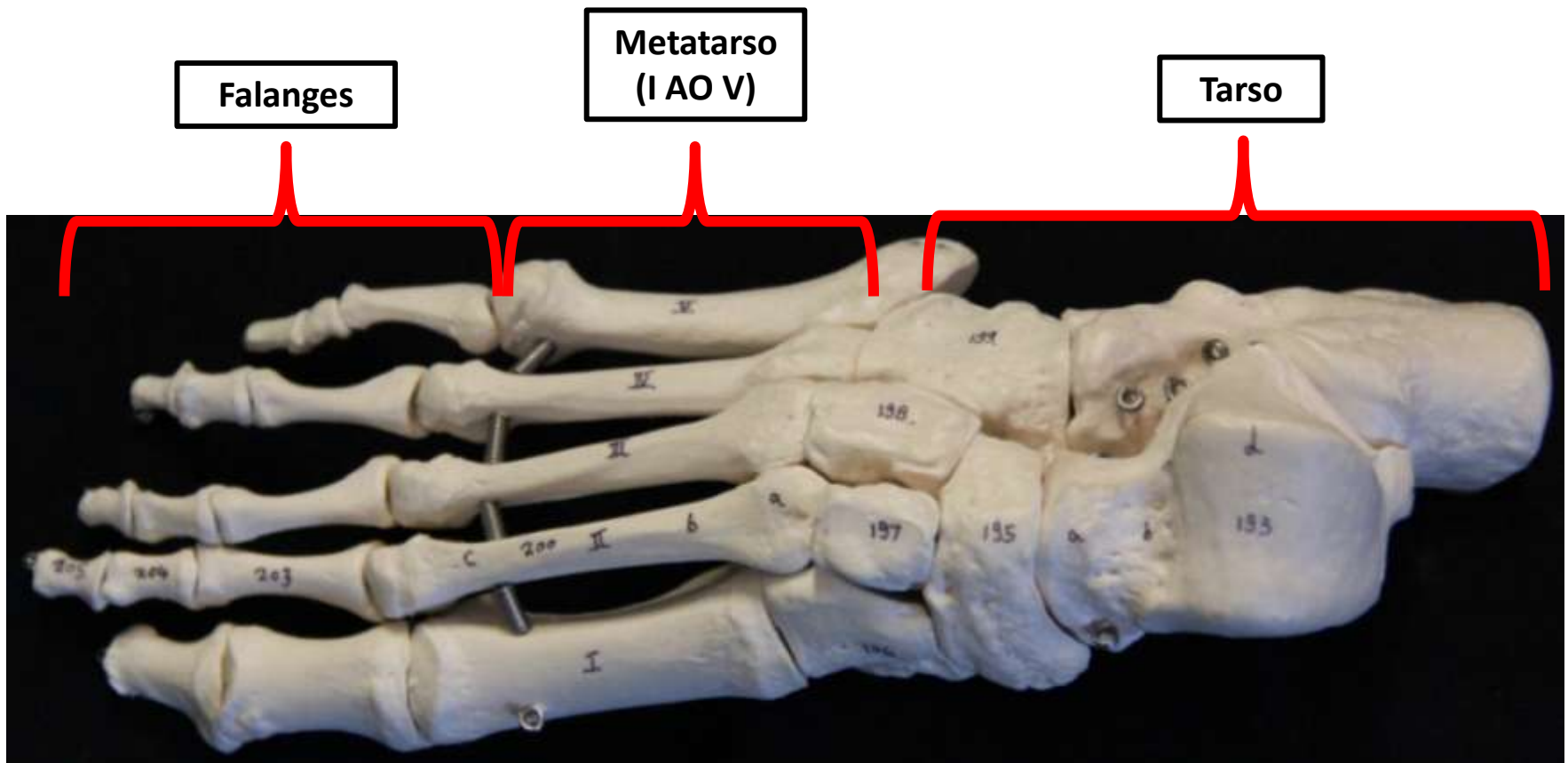


Face articular superior

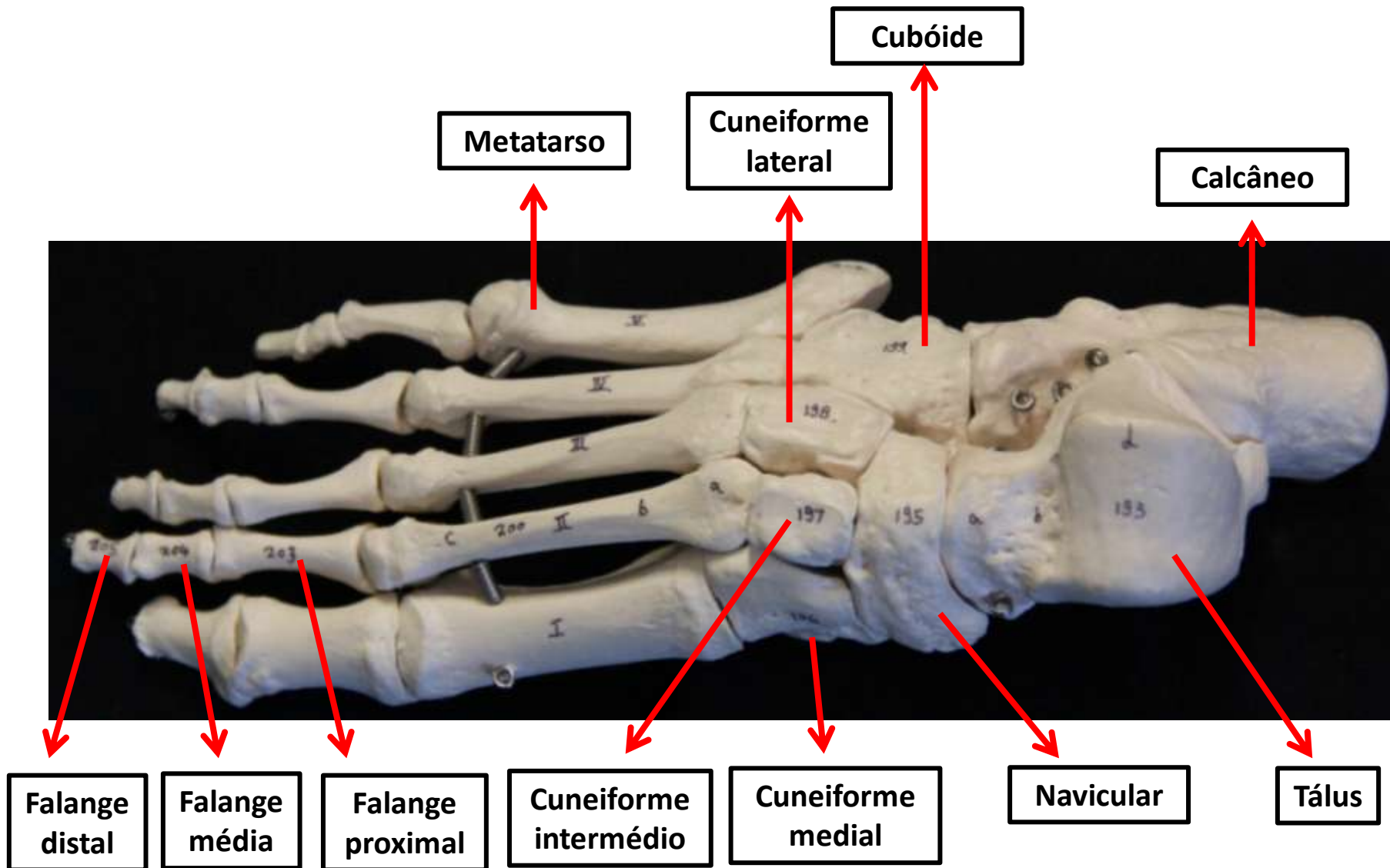
Tíbia – Vista posterior

Fíbula

Pé



Pé



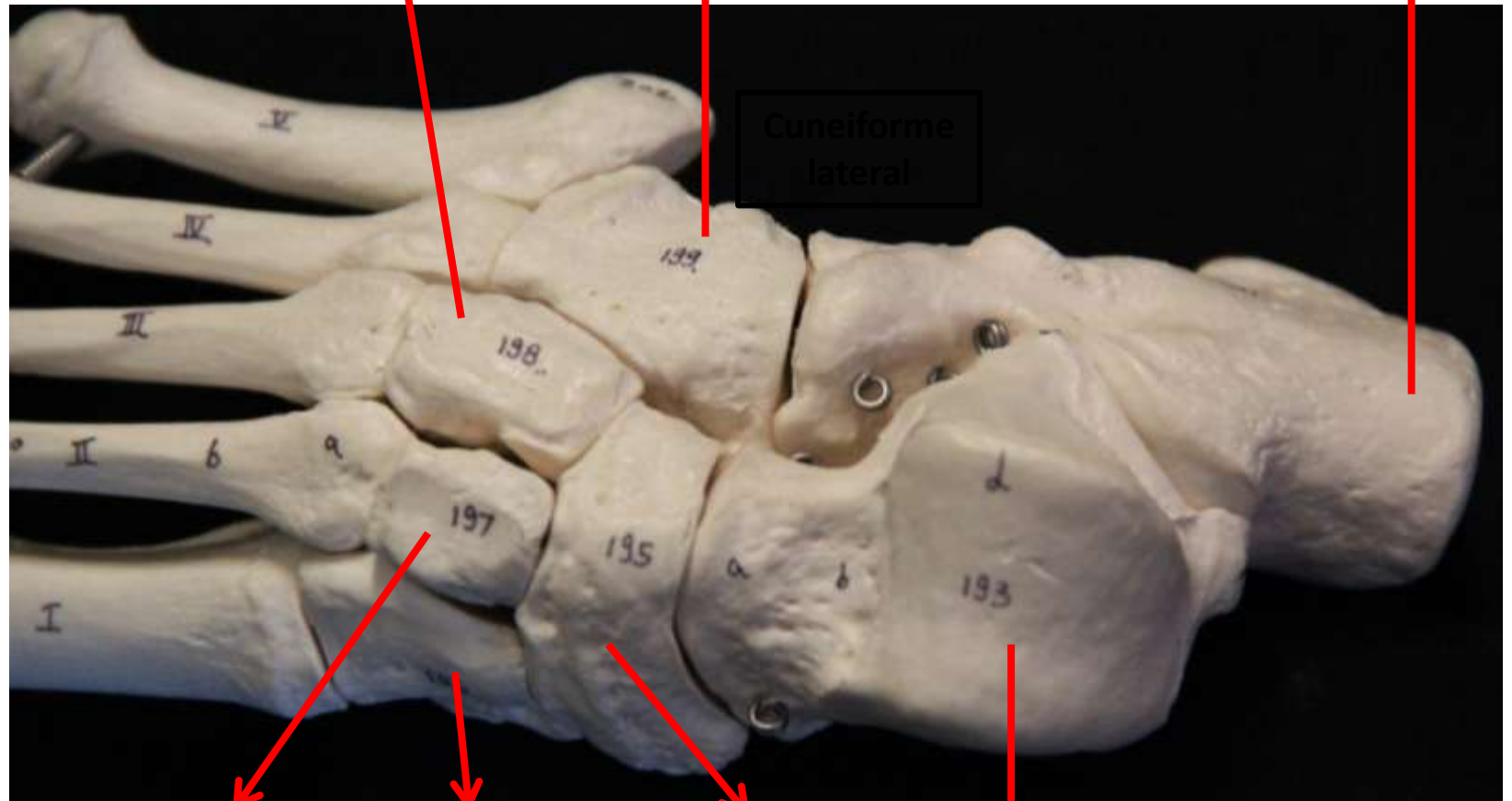
Pé – Vista anterior

Ossos do Tarso

Cuneiforme lateral

Cubóide

Calcâneo



Cuneiforme intermédio

Cuneiforme medial

Navicular

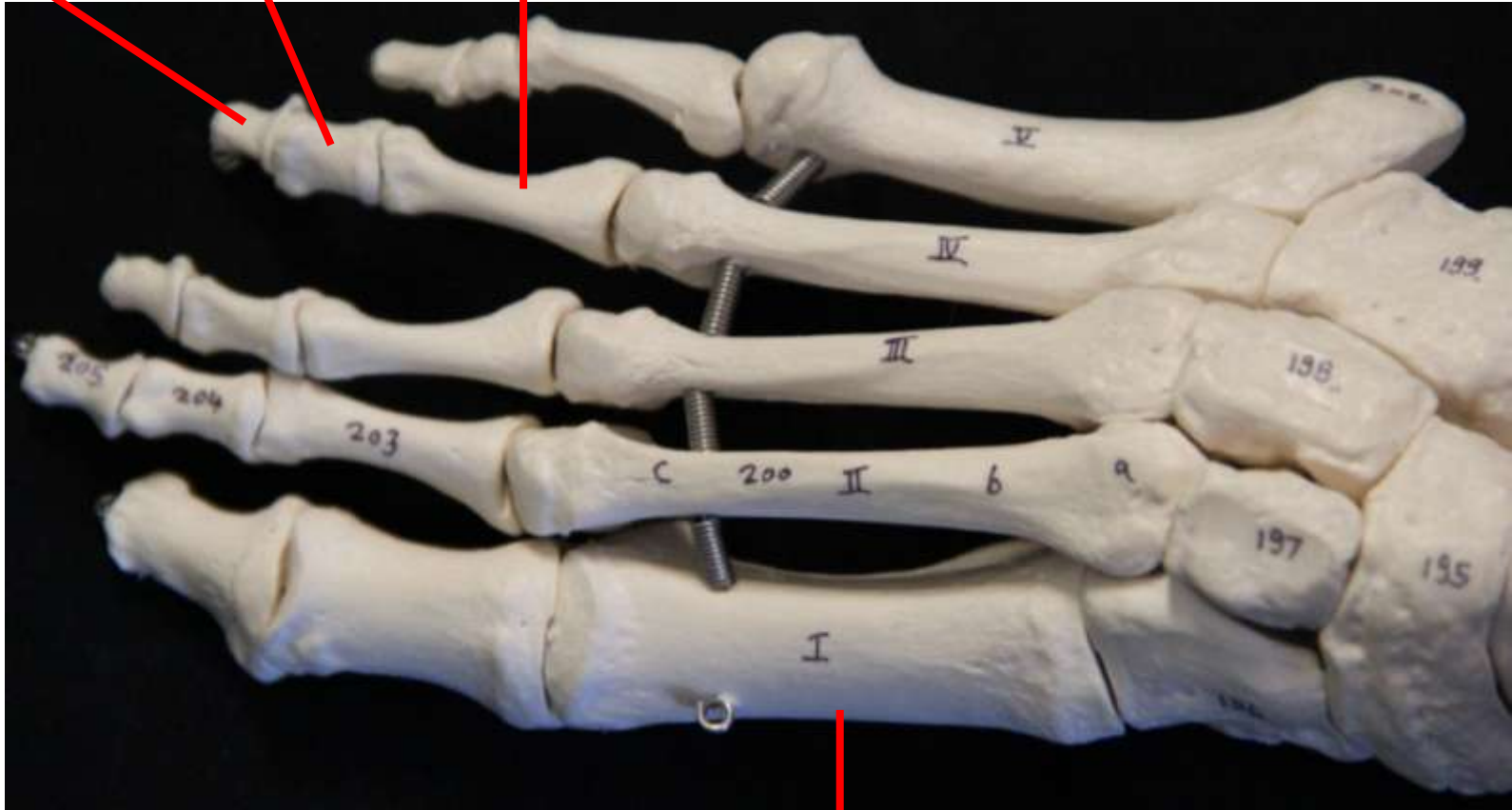
Tálus

Vista anterior

Falange distal

Falange média

Falange proximal



Metatarso